Fibrillary Glomerulonephritis

Frank Bridoux, Vincent Javaugue, Guy Touchard

Service de Néphrologie, CHU Poitiers, France
CNRS UMR 7276 – INSERM U 1262

Centre de référence maladies rares « Amylose AL et autres maladies par dépôt d'immunoglobulines monoclonales »

Actualités Néphrologiques Jean Hamburger
2022

Glomerular Diseases with Organized Immunoglobulin Deposits

	Immunoglobulinic amyloidosis	Fibrillary GN	Immunotactoid GP	Cryoglobulinic GN
Ultrastructural pattern	Fibrils	Fibrils	Microtubules	Microtubules Crystals
Congo red	Positive	Negative	Negative	Negative
Mean external diameter	7-10 nm	10-20 nm	10-60 nm	8-60 nm
Composition of deposits	**AL** : LC ($\lambda > \kappa$) **AH** : truncated HC $\gamma 1 > \gamma 4 > \gamma 3$ α, δ	IgG4 +++ IgG1 ++ **$\kappa + \lambda$**	IgG1 IgG2 IgG3 $\kappa > \lambda$	**Type II:** IgM anti-IgG ($\kappa > \lambda$) **Type I:** IgG1, IgG3 IgM IgA ($\kappa > \lambda$)

Adapted from: Touchard G. Monoclonal gammopathies and the Kidney. Kluwer Academic Publishers, 2003

Fibrillary GN and ITGP : Diagnostic Criteria

Fibrillary GN	Immunotactoid GP **GN with organized microtubular monoclonal Ig deposits (GOMMID)**
Fibrils 10 to 20 nm No central lumen Pseudo-amyloid disposition Congo red negative	**Microtubules** 10 to 60 nm Hollow core (magnification < 50.000) Arranged in parallel arrays (at least focally)
IgG (+ complement components)	
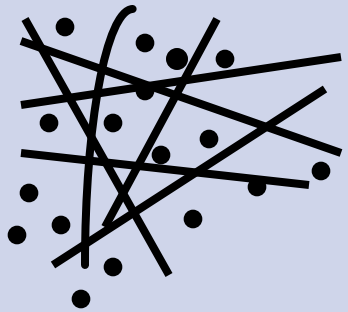	

Alpers CE. Am J Kidney Dis 1992; 19: 185
Bridoux F et al. Kidney Int 2002;62:1764-75

Fibrils : Amyloidosis *vs* FGN

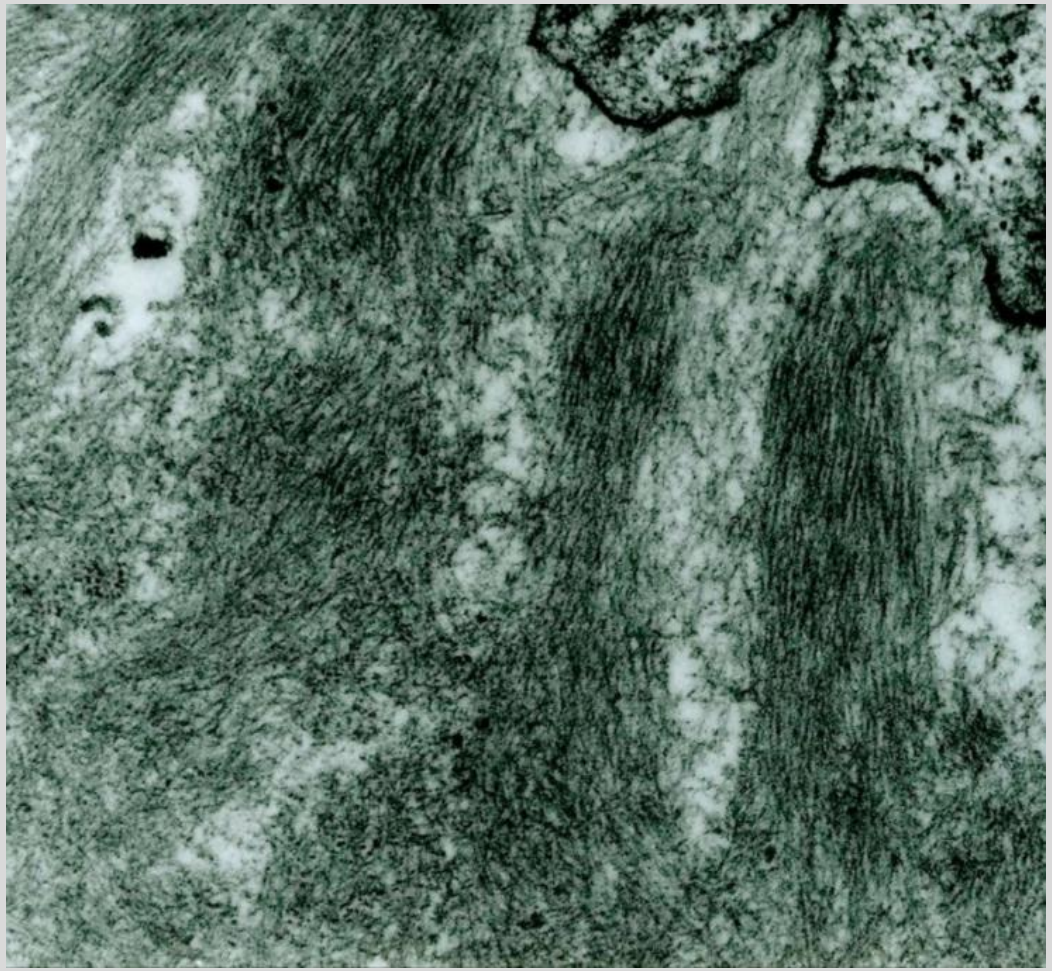

AL amyloidosis

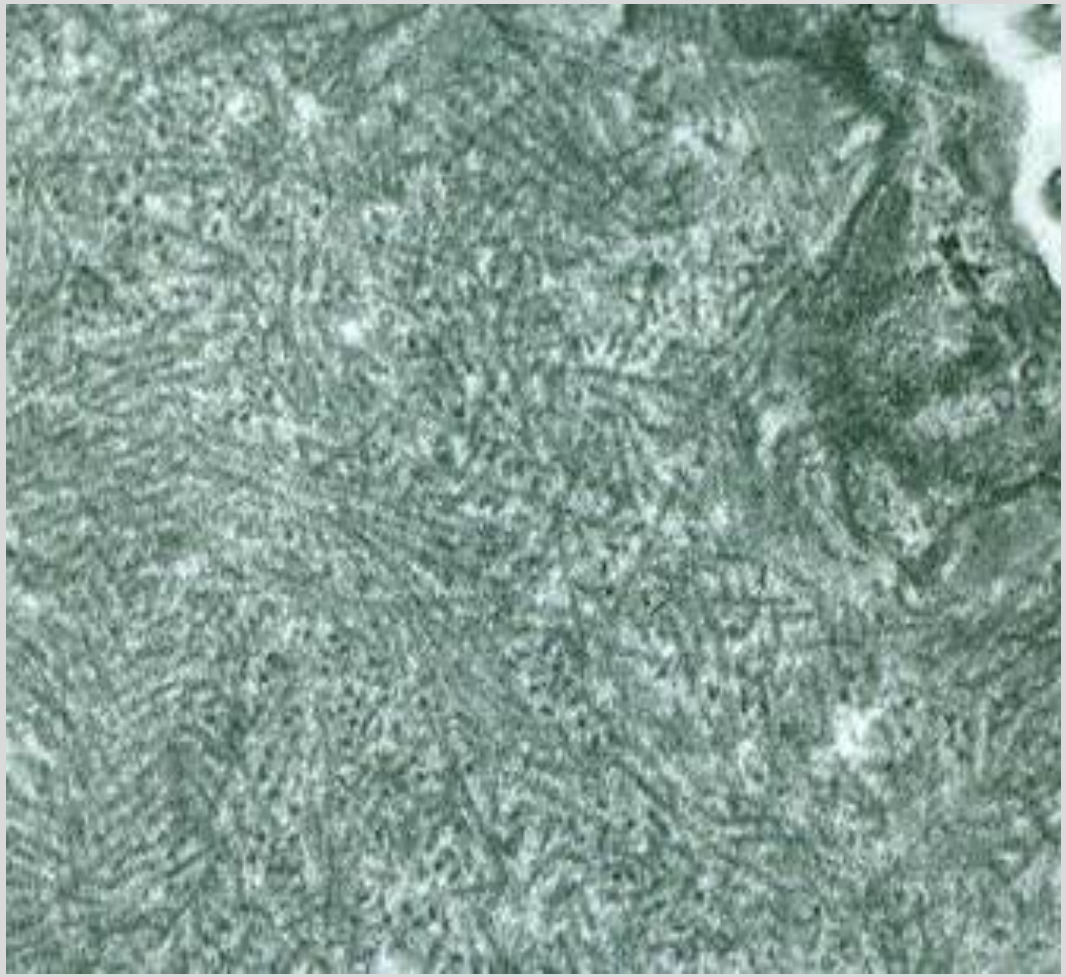

Fibrillary GN

Microtubules: ITGP *vs* Cryoglobulinemic GN

ITGP

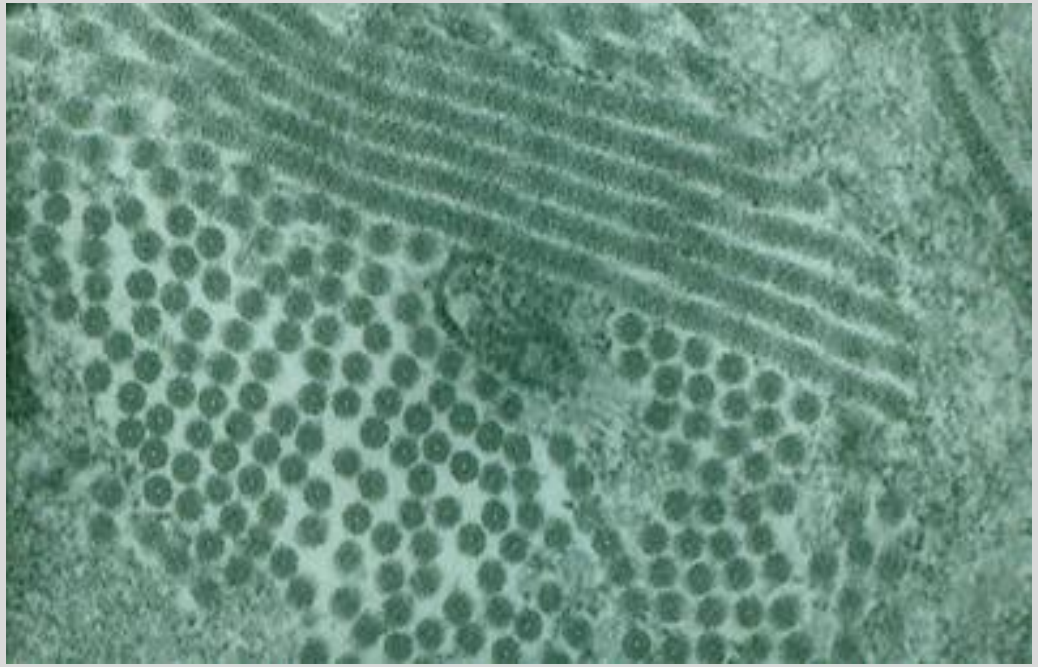



Cryo. I

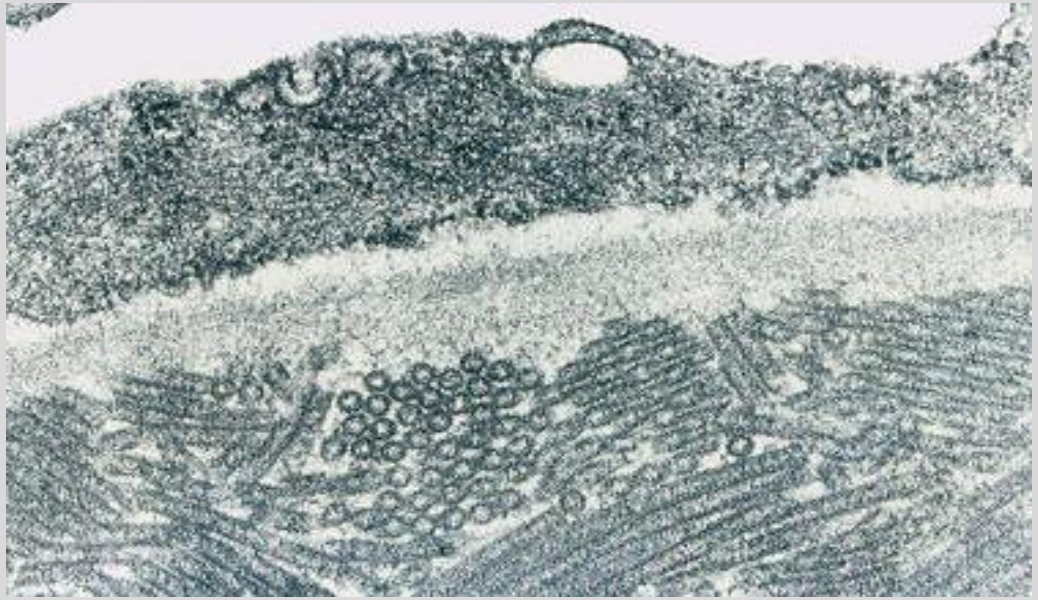

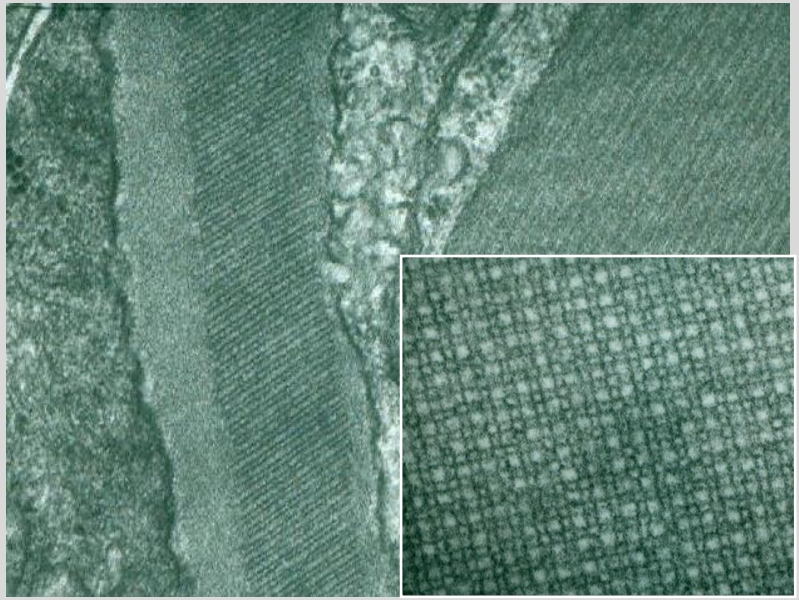

FGN : Light Microscopy

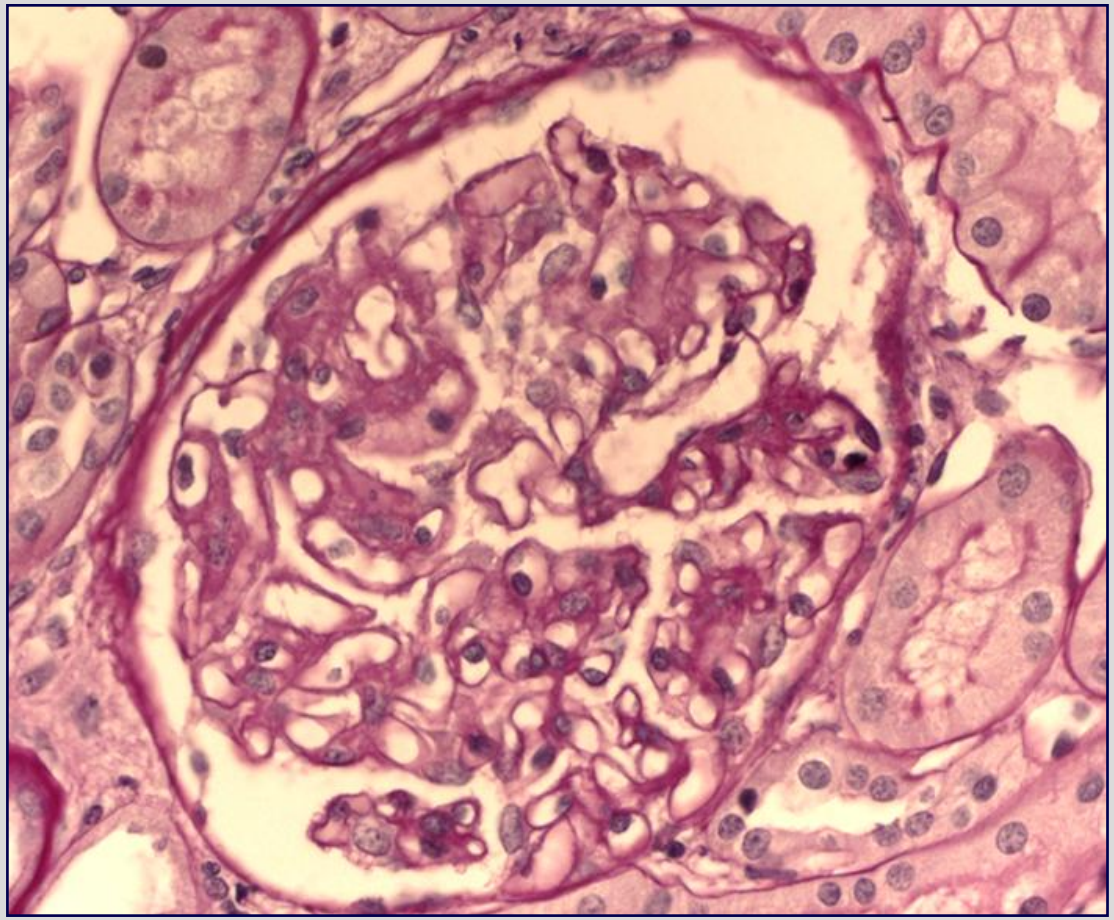

Mesangial GN

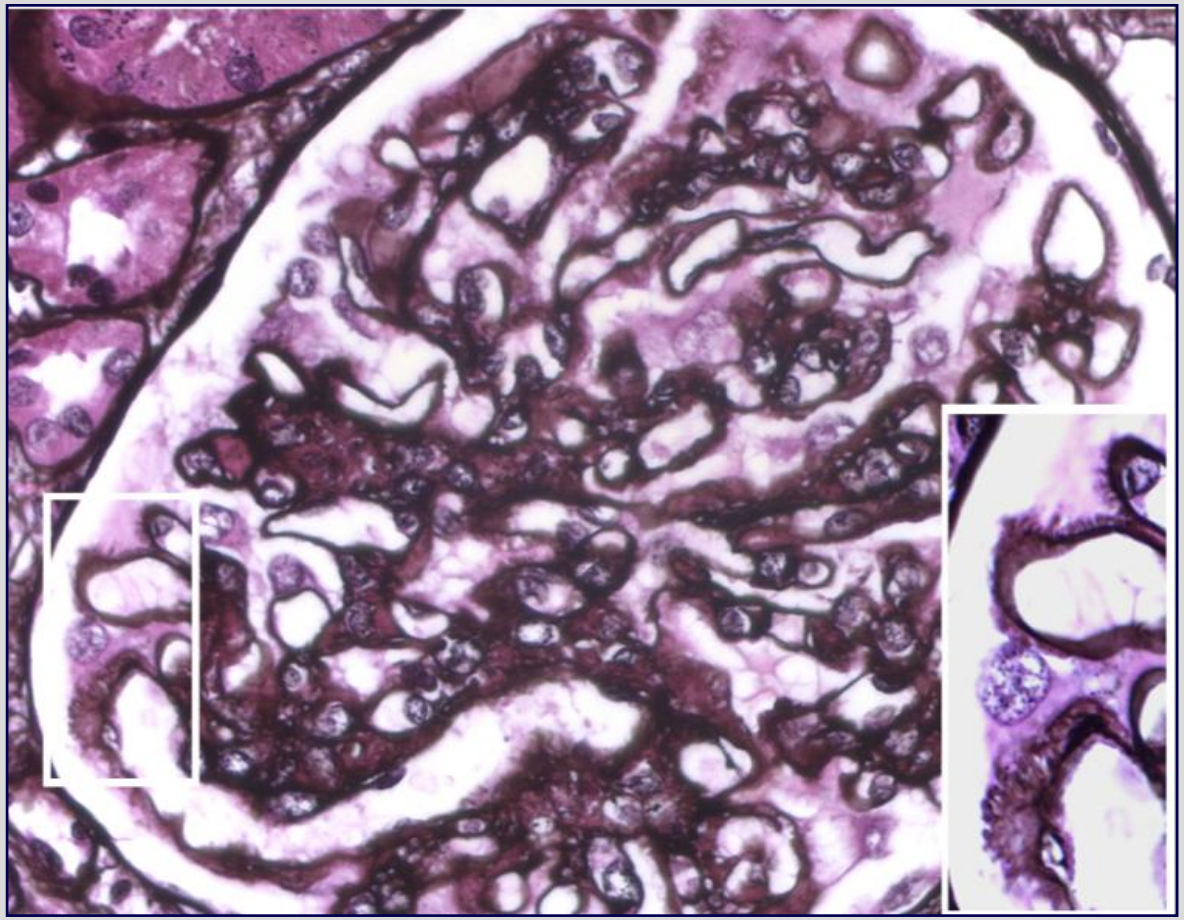

Membranous GN

Javaugue V et al. Am J Kidney Dis 2013; 62:679-90

FGN : Light Microscopy

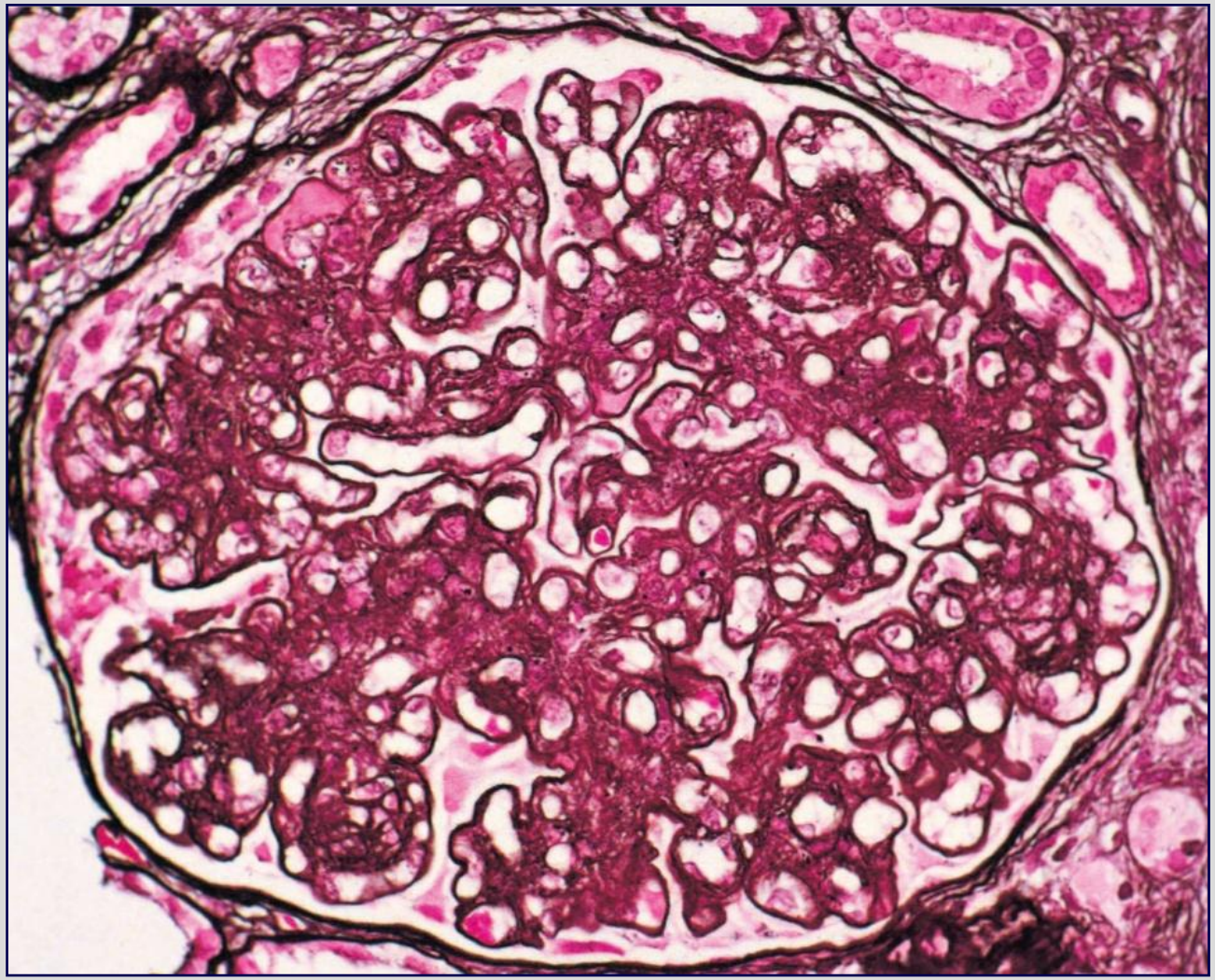

Membranoproliferative GN

Rosenstock JL et al. Kidney Int 2003; 63: 1450-61

FGN : Immunofluorescence Microscopy

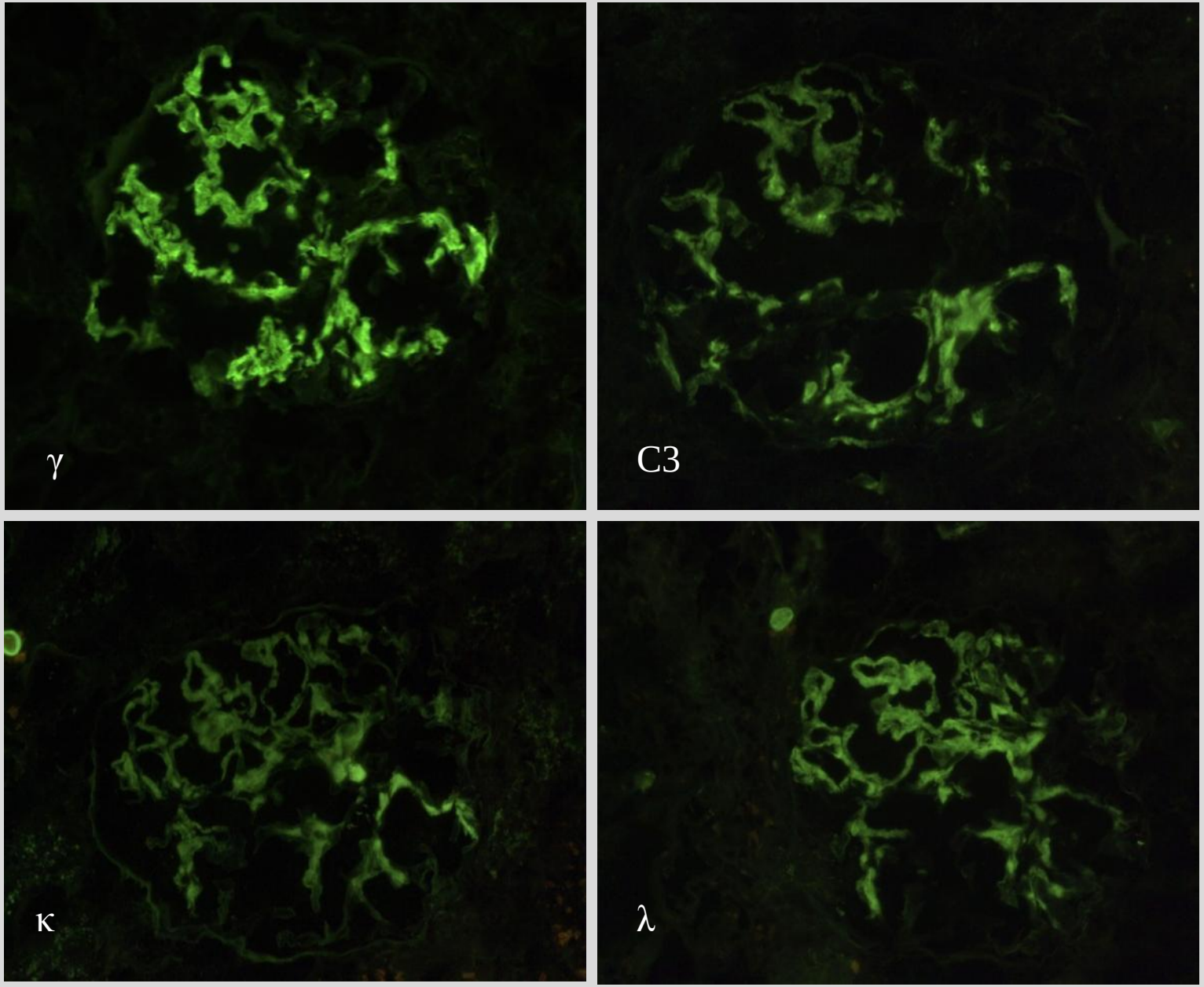

FGN : Immunofluorescence Microscopy

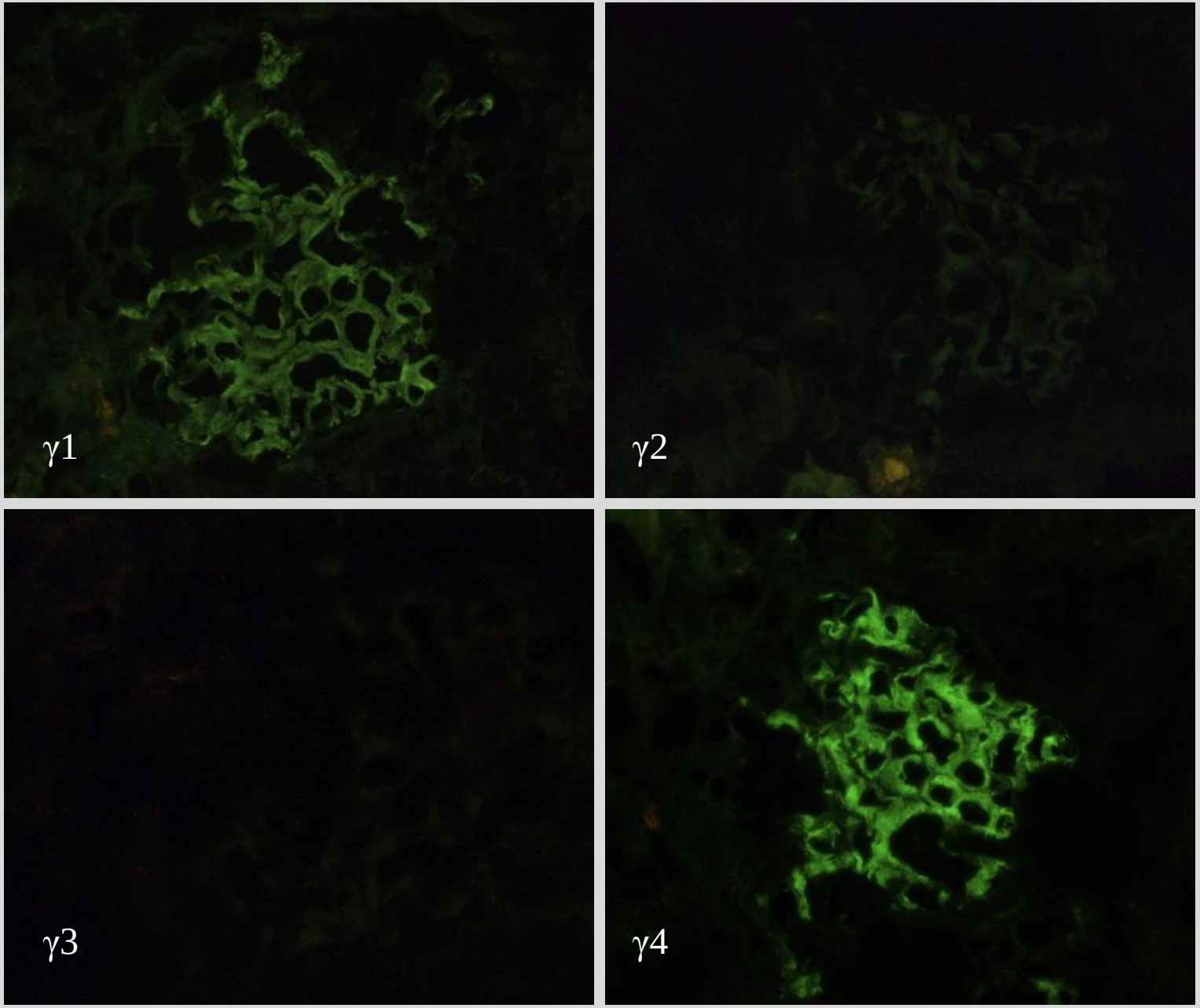

Polyclonal IgG (IgG4 +++, IgG1++) in 80-96% of patients

FGN : Electron Microscopy

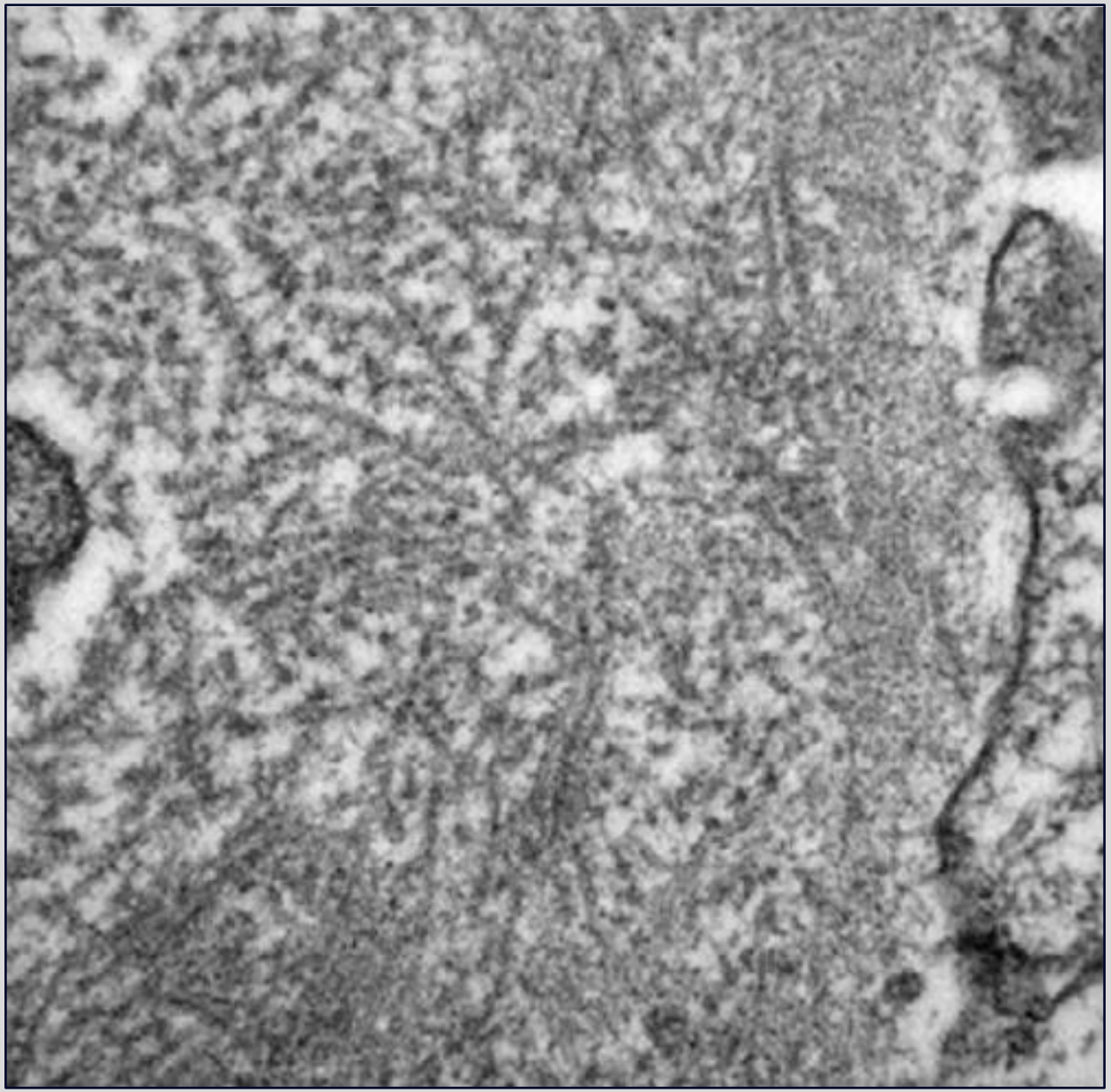

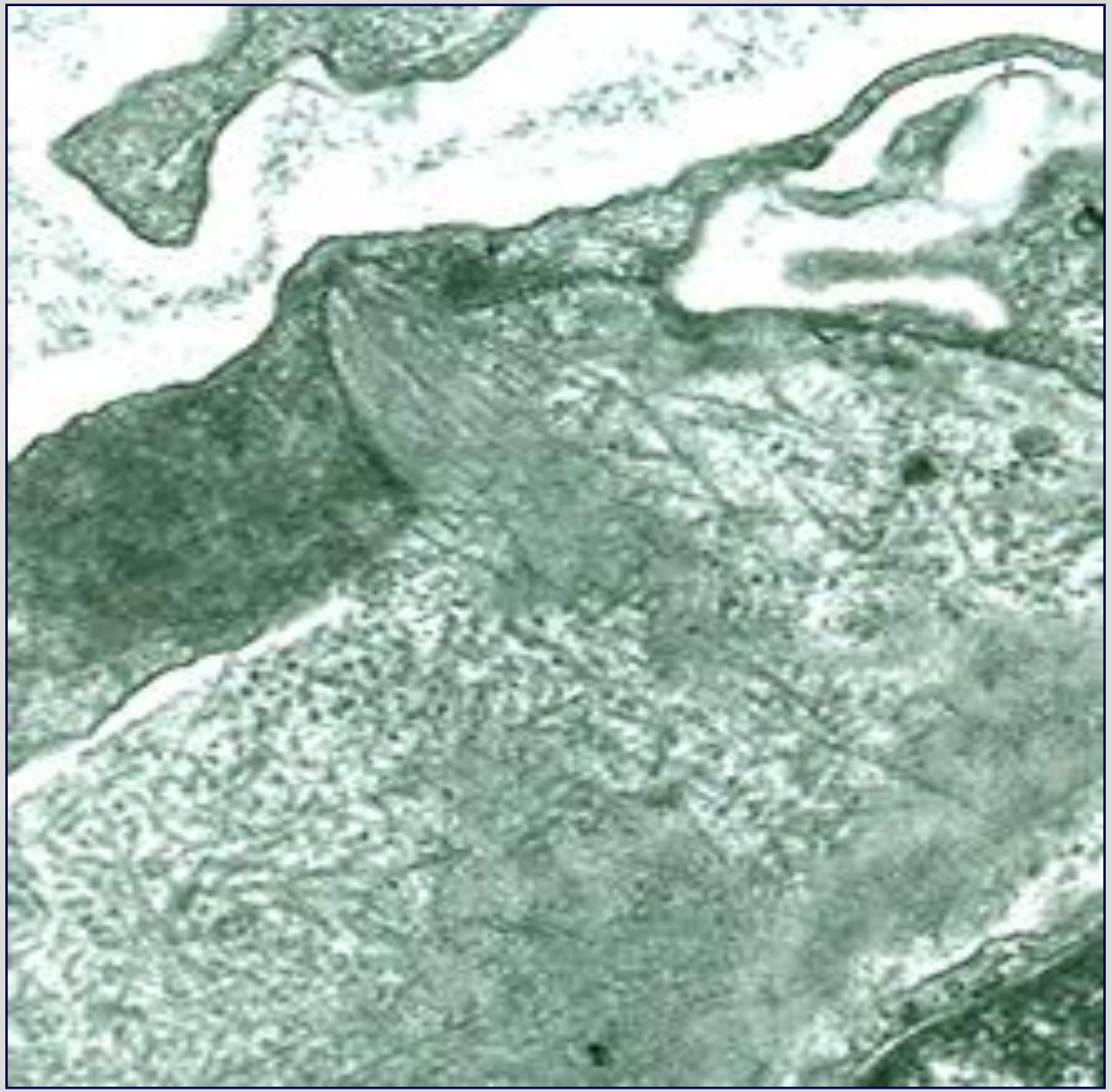

Immunotactoid Glomerulopathy/GOMMID

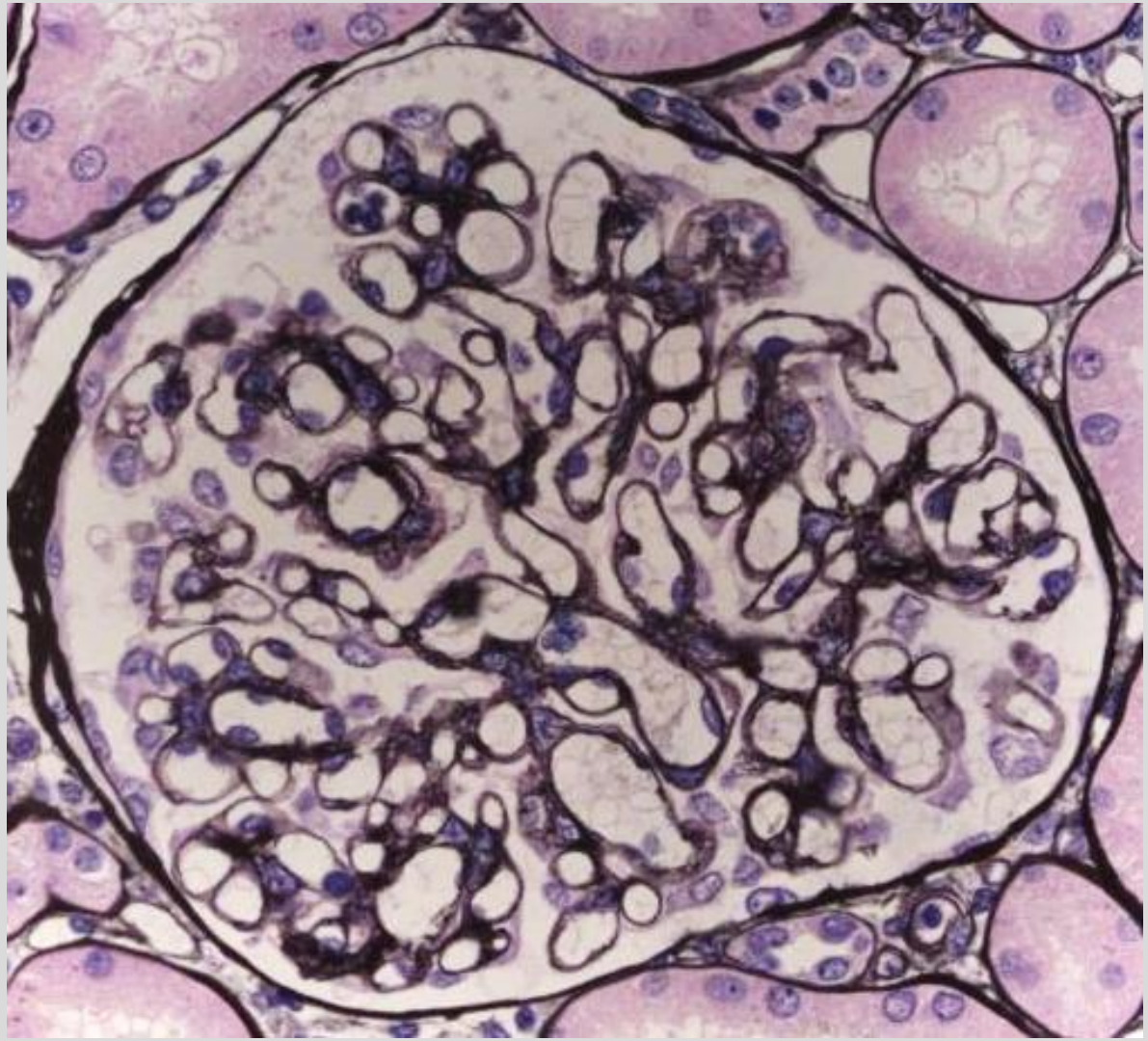

Atypical MGN

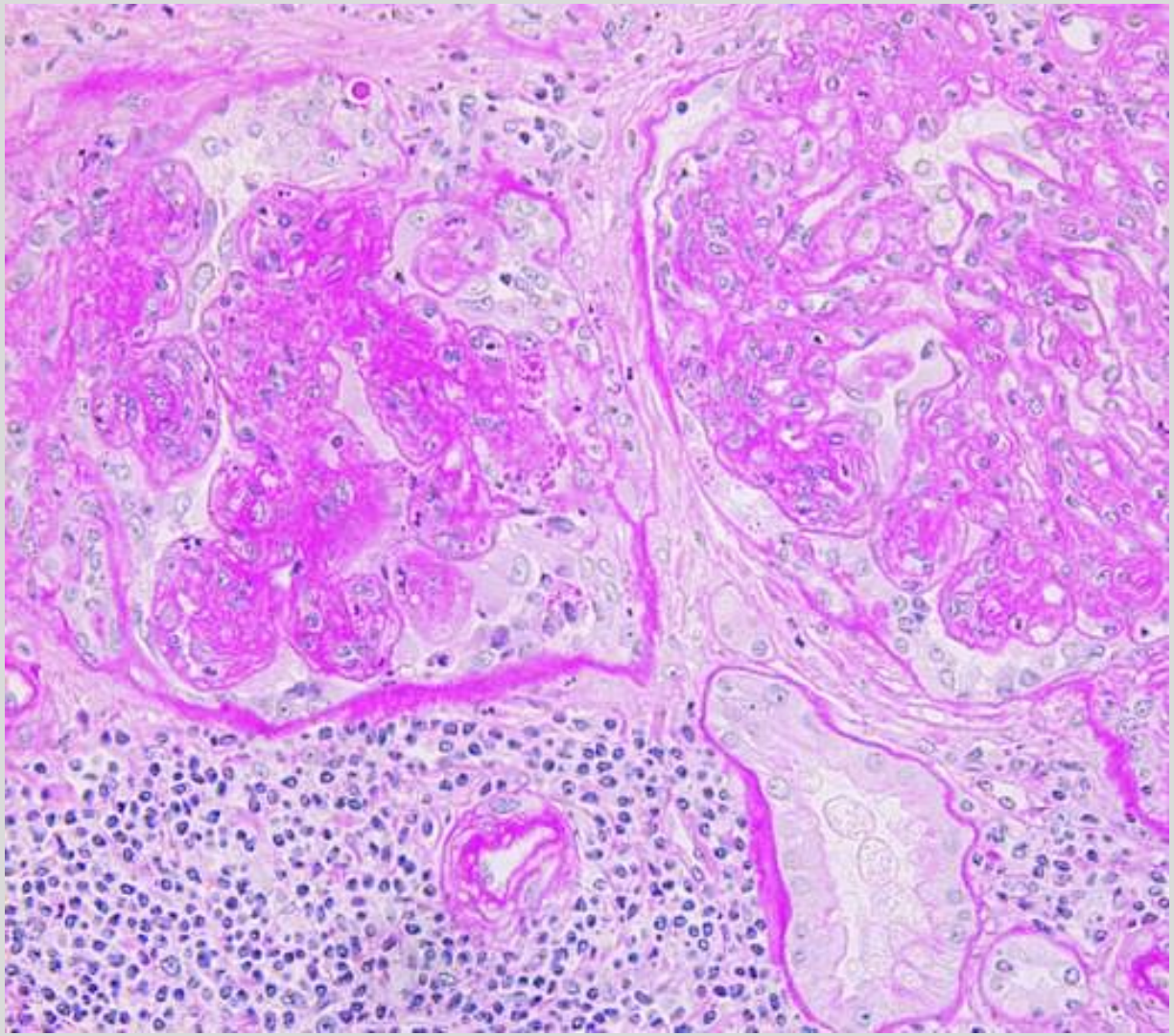

MPGN and malignant B-cell infiltration

Javaugue V et al. Kidney Int 2021;99:421-30

Immunotactoid Glomerulopathy/GOMMID

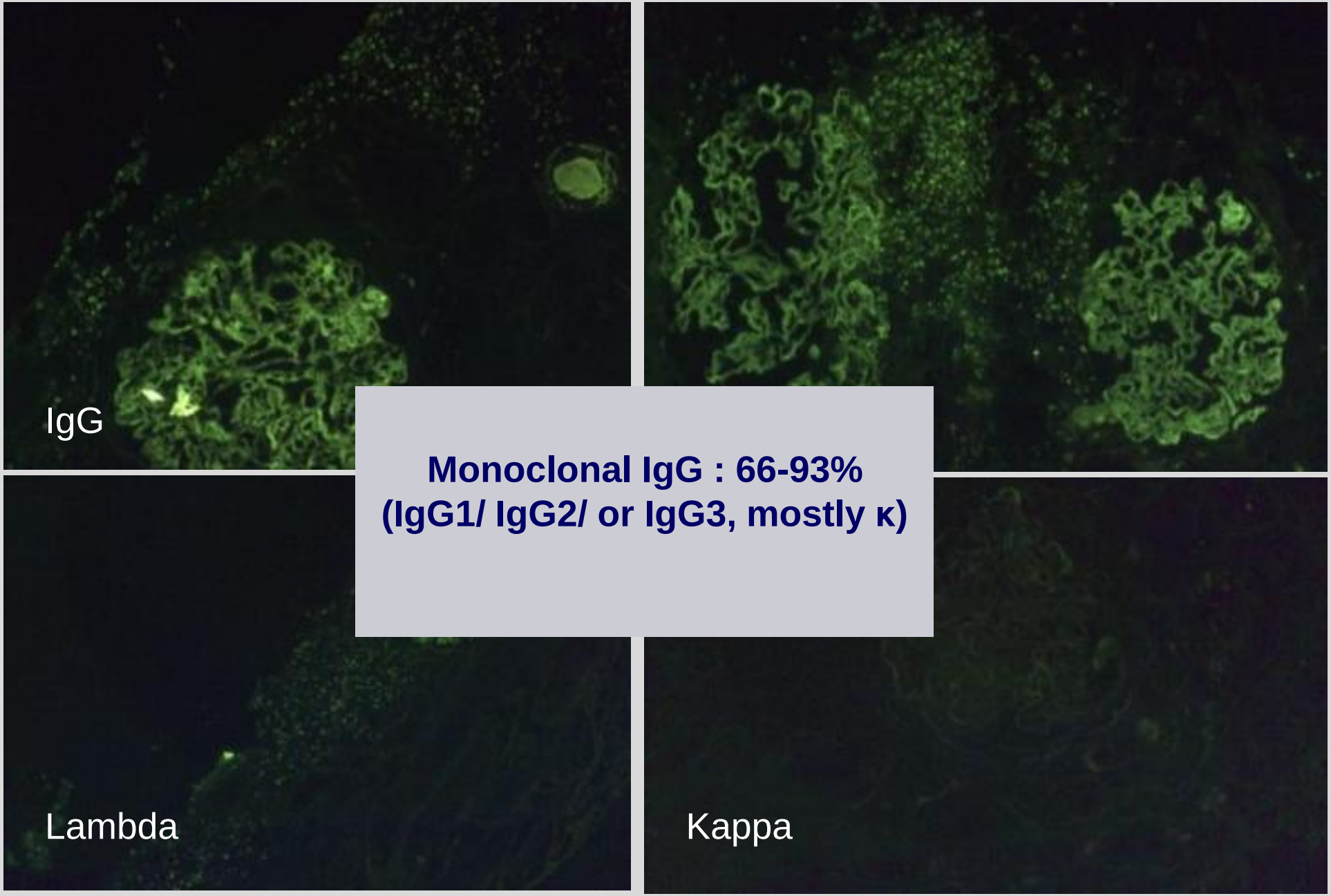

Monoclonal IgG : 66-93%
(IgG1/ IgG2/ or IgG3, mostly κ)

Immunotactoid Glomerulopathy/GOMMID

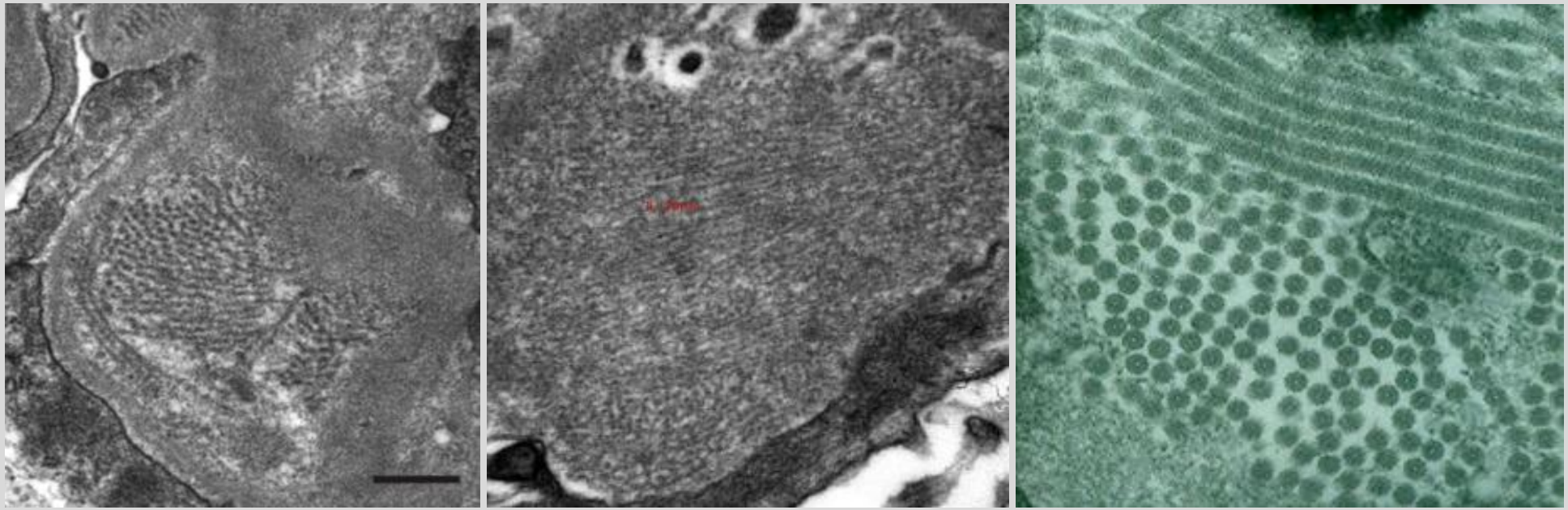

Glomerulus

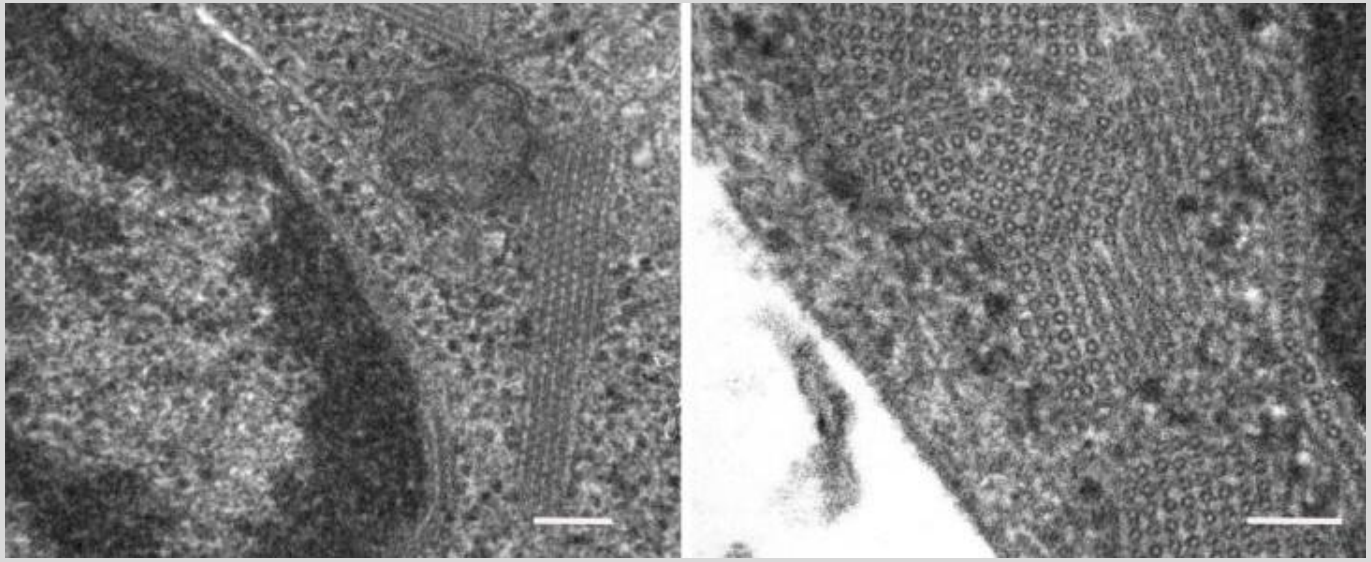

Clonal B-lymphocyte

FGN and ITGP : Variants of the Same Entity?

Yes

- Similar renal manifestations, poor prognosis
- Common light and IF microscopic features
- Distinction between fibrils and microtubules without relevance

Korbet SM et al. Am J Kidney Dis 1991; 17: 247
Brady HR. Kidney Int 1998; 53: 1421

No

- ITGP most commonly associated with B-cell clonal disorders
- IgG glomerular deposits : monoclonal in ITGP *vs* polyclonal (IgG4 ++) in FG
- ITGP may respond to cytotoxic therapy

Alpers CE. Am J Kidney Dis 1992; 19: 185
Fogo A, et al. Am J Kidney Dis 1993; 22: 367
Touchard G, et al. Adv Nephrol Necker Hosp 1994; 23: 149
Bridoux F, et al. Kidney Int 2002;62:1764-75

FGN : Clinical Characteristics

- **Frequency** : 0.4-1.4% of native kidney biopsies
- **Clinical presentation :**
  - Median age at diagnosis ~ 57 years (49-60 years)
  - No extra-renal fibrillary deposits
  - Proteinuria (> 2 g/24h) : ~ 90%
  - Hypertension, microhematuria, nephrotic syndrome, kidney failure ~ 50%
  - RPGN rare (~ 10%)
  - Hypocomplementemia <5%, absence of detectable cryoglobulins, normal serum IgG4 level
- **Disease associations :**
  - Variable association (30-60%) with auto-immune disorders (3-30%), non hematologic cancers (5-15%) and chronic viral (HCV++) infection (5-17%)
  - B-cell clonal disorder < 5%, serum/urine monoclonal gammopathy <15%
  - Rare reports of familial FGN
  - Association with HLA B35 and DQ2 antigens: genetic background?

Nasr SH et al. Clin J Am Soc Nephrol 2011; 6: 775-84
Javaugue V et al. Am J Kidney Dis 2013; 62:679-90
Andeen NK, et al. KIR 2020; 5; 1325-7

Immunotactoid Glomerulopathy/GOMMID

- Frequency : 0.06% of native kidney biopsies
- Clinicopathologic characteristics
  - Age at diagnosis ~ 60 yrs
  - Renal manifestations: chronic glomerular disease
    Proteinuria (>2 g/24h) : >90%
    Nephrotic syndrome, hematuria, renal insufficiency, hypertension > 50%
  - Extra-renal deposits exceptional: skin, peripheral nerve
- Hematological characteristics
  - Detectable monoclonal gammopathy >60%
  - B-cell clonal disorder ~ 100% (mostly lymphocytic) (MGRS ~ 50%, CLL~ 50%)
  - Hypocomplementemia ~ 30%

Javaugue V, et al. Kidney Int 2021; 99; 421-30
Nasr SH, et al. Kidney Int. 2021;99:410-20

Table 1 | Baseline characteristics

Characteristics	No. of patients (N = 27)
Clinical characteristic	
Age, yr	61 (30–79)
Male sex	18 (67)
Hypertension	15 (56)
Proteinuria, g/d	6 (1–23)
Nephrotic syndrome	19 (70)
Microscopic hematuria	20 (74)
Serum creatinine, mg/d	1.5 (0.6–6.5)
eGFR, ml/min per 1.73 m^2	56 (11–108)
Chronic kidney disease ≥3	17 (63)
Extrarenal manifestations	1 (4)
Hematologic characteristics	
Measurable SPEP and/or UPEP monoclonal spike	4 (15)
Positive serum and/or urine immunofixation	19 (70)
Abnormal serum-free light chain ratio	3/16 (19)
IgG subclass by serum immunoblot analysis (n = 16)	
IgG1	9 (56)
IgG2	5 (31)
IgG3	2 (13)
IgG4	0
Diagnosis	
CLL[a]	10 (37)
Small lymphocytic lymphoma	3 (11)
MGRS	14 (52)
Underlying B-cell clone	
Lymphocytic	16 (60)
Plasmacytic	2 (7)
Unknown	9 (33)

DNAJB9 : Specific Tissue Biomarker for FGN

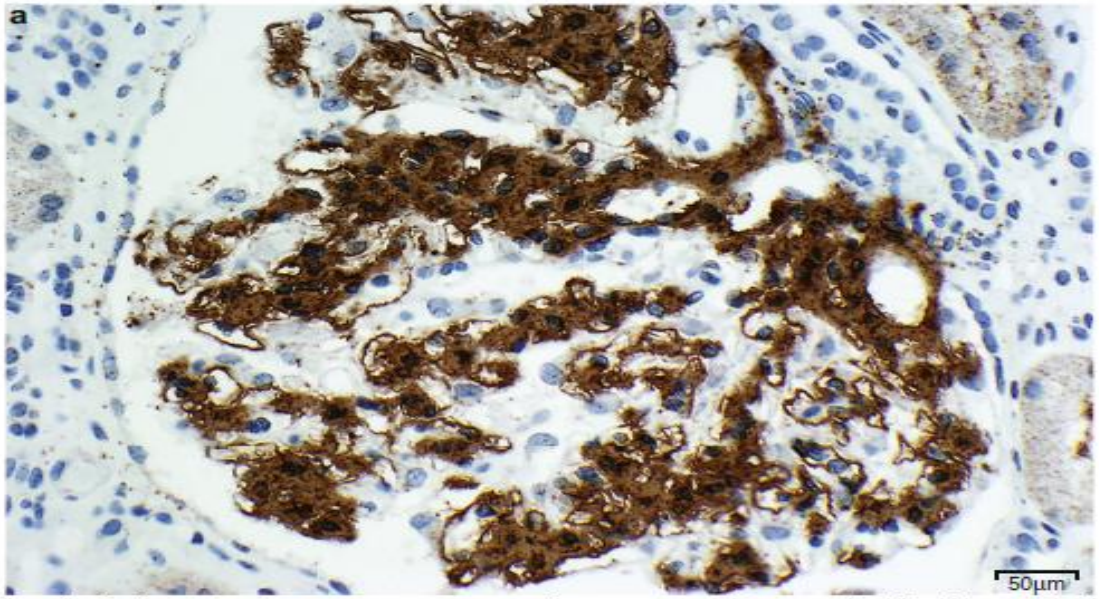

b

Probability legend:
- Over 95%
- 80% to 94%
- 50% to 79%
- 20% to 49%
- 0% to 19%

Bio view:
Identified proteins (67/69)
Including 7 decoys

#	Visable?	Starred?		Accession number	Molecular weight	Protein grouping ambiguity	Presample blank	Sample #1	Sample #2
1	✓	★	DnaJ homolog subfamily B mem...	DNJB9_HU...	26 kDa			22	15
2	✓	☆	Actin, cytoplasmic 1	ACTB_HUM...	42 kDa	★		73	60
3	✓	☆	Hemoglobin subunit beta	HBB_HUMAN	16 kDa	★		41	38
4	✓	☆	Complement C3	CO3_HUMAN	187 kDa			28	18
5	✓	☆	Vimentin	VIME_HUM...	54 kDa			15	38
6	✓	☆	Usherin	USH2A_HU..	576 kDa			13	11
7	✓	☆	Hemoglobin subunit alpha	HBA_HUMAN	15 kDa			21	21
8	✓	☆	Serum albumin	ALBU_HUM...	69 kDa			15	23
9	✓	☆	Protocadherin Fat 2	FAT2_HUM...	479 kDa			1	1
10	✓	☆	Complement C4-B	CO4B_HUM...	193 kDa			20	11

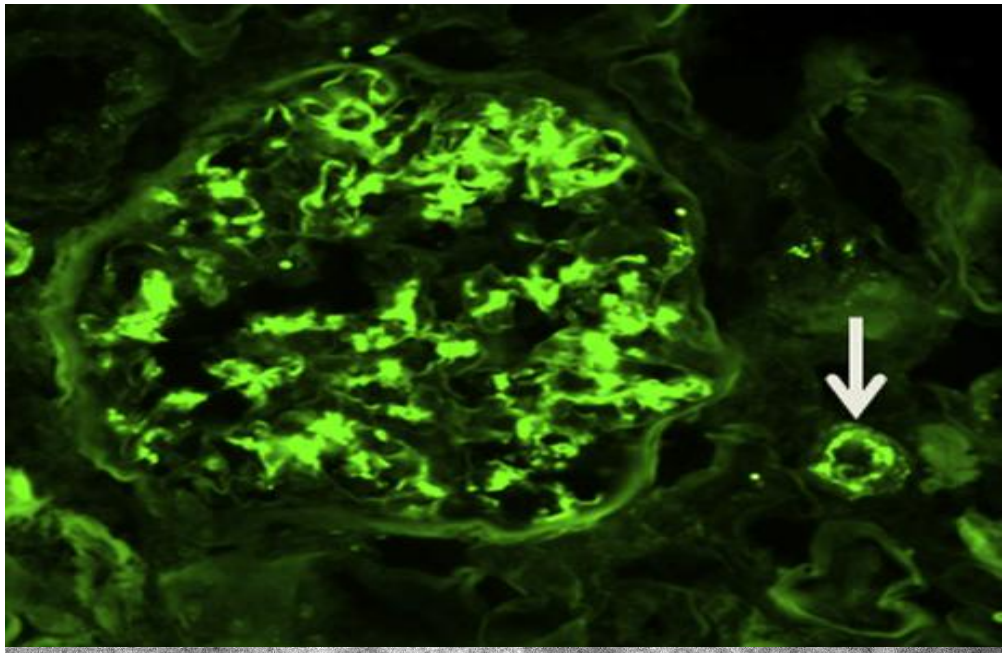



Nasr SH, et al. Kidney Int Rep. 2017;3:56-64
Andeen NK, et al. J Am Soc Nephrol. 2018;29:231-9
Dasari S, et al. J Am Soc Nephrol. 2018;29:51-6.

DNAJB9 : Specific Tissue Biomarker for FGN

- **DNA J homolog subfamily B member 9 (DNAJB9)**
  - Highly enriched in glomeruli of patients with FGN, not in other glomerular diseases or healthy subjects
  - DNAJB9 IHC : 98% sensitivity and >99% specificity for the diagnosis of FGN

- **Utility of DNAJB9 IHC in the diagnosis of FGN :**
  1. Alleviates the need for electron microscopy
  2. Provides prompt diagnosis
  3. Distinguishes FGN from other lesions in the differential diagnosis
  4. Confirms the diagnosis of FGN when concurrent with other diseases

Nasr SH, et al. Kidney Int Rep. 2017;3:56-64
Andeen NK, et al. J Am Soc Nephrol. 2018;29:231-9
Dasari S, et al. J Am Soc Nephrol. 2018;29:51-6.

DNAJB9 and Pathogenesis of FGN

- DnaJ heat shock protein family (Hsp40) member B9 (DNAJB9)
  - Co-chaperone to HSP 70s (BiP)
  - Depresses UPR / ER stress
  - Binds to aggregation-prone peptides
  - Anti-inflammatory and anti-apoptotic effects
  - Ubiquitous, highest expression in cells with well developed ER (liver, placenta, kidney)

Nasr SH, et al. Kidney Int 2019; 65: 1269-72
Nasr SH, Fogo AB. Kidney Int. 2019;96:581-92
Avasare RS, et al. Kidney Int Rep 2020; 5: 368-72

DNAJB9 and Pathogenesis of FGN

- Putative autoantigen in fibrillary glomerulonephritis ?
  - Co-localization of staining for DNAJB9 and IgG within glomerular deposits
  - High serum DNAJB9 levels in FGN patients, but no evidence for circulating DNAJB9 autoantibodies
  - Glomerular accumulation of DNAJB9 not due to local UPR upregulation in glomeruli
  - DNAJB9 may secondarily bind to misfolded IgG molecules by recognizing aggregation-prone motifs

DNAJB9 as a potential autoantigen in FGN

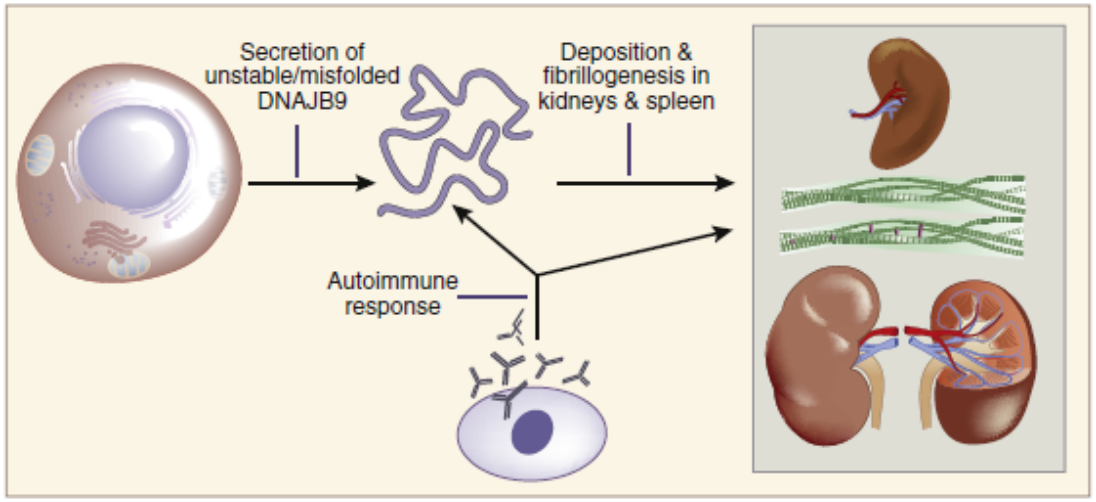

DNAJB9 secondarily binds to misfolded IgG

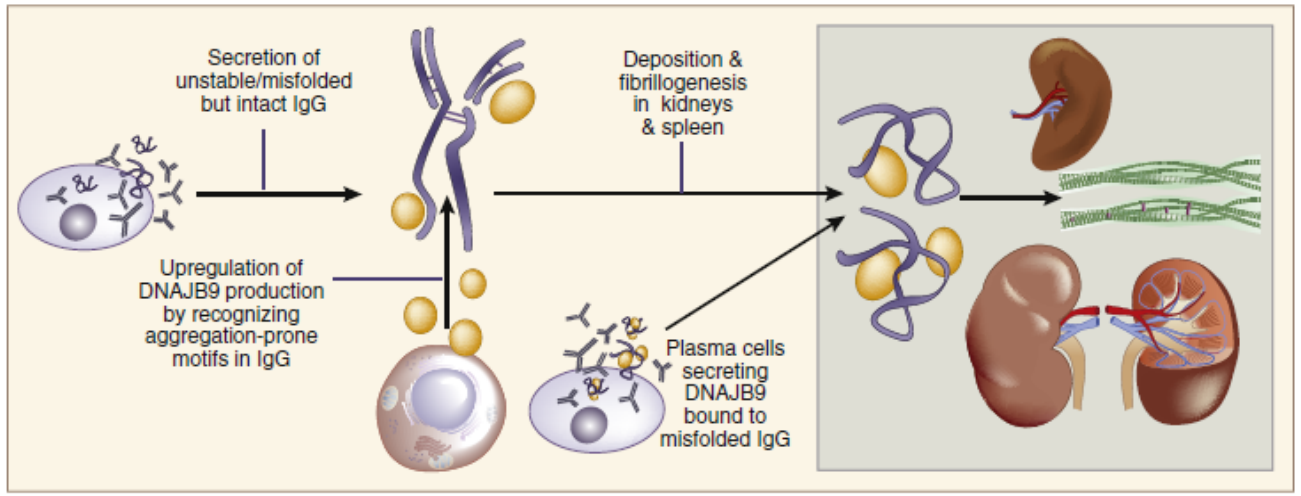

Nasr SH, Fogo AB. Kidney Int. 2019;96:581-92

Avasare RS, et al. Kidney Int Rep 2020; 5: 368-72

2015 Classification of MGRS-Associated Renal Lesions

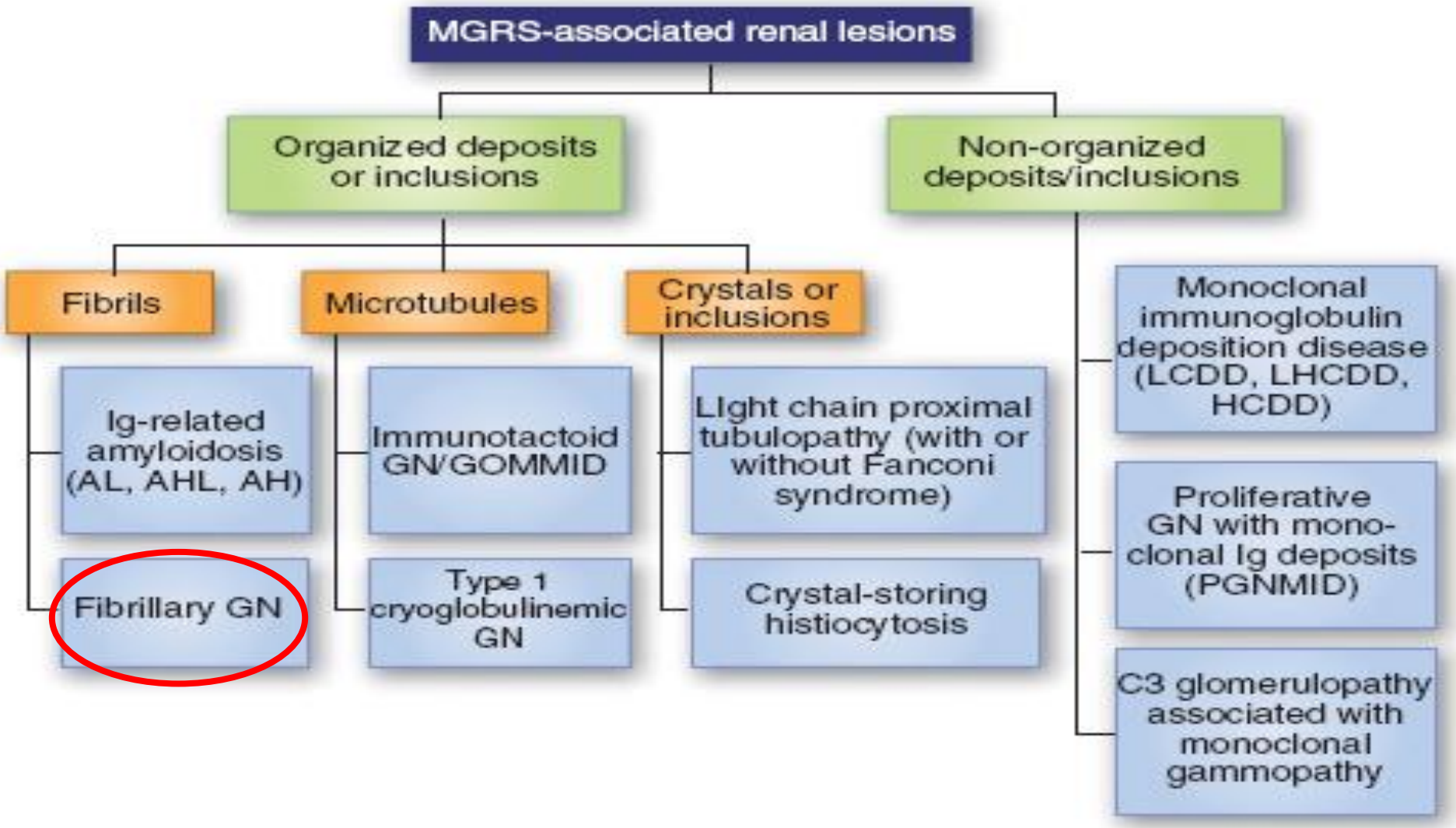

Bridoux F. Kidney Int 2015, Leung N Nat Rev Nephrol 2019

DNAJB9 monotypic FGN is not associated with monoclonal gammopathy in the vast majority of cases

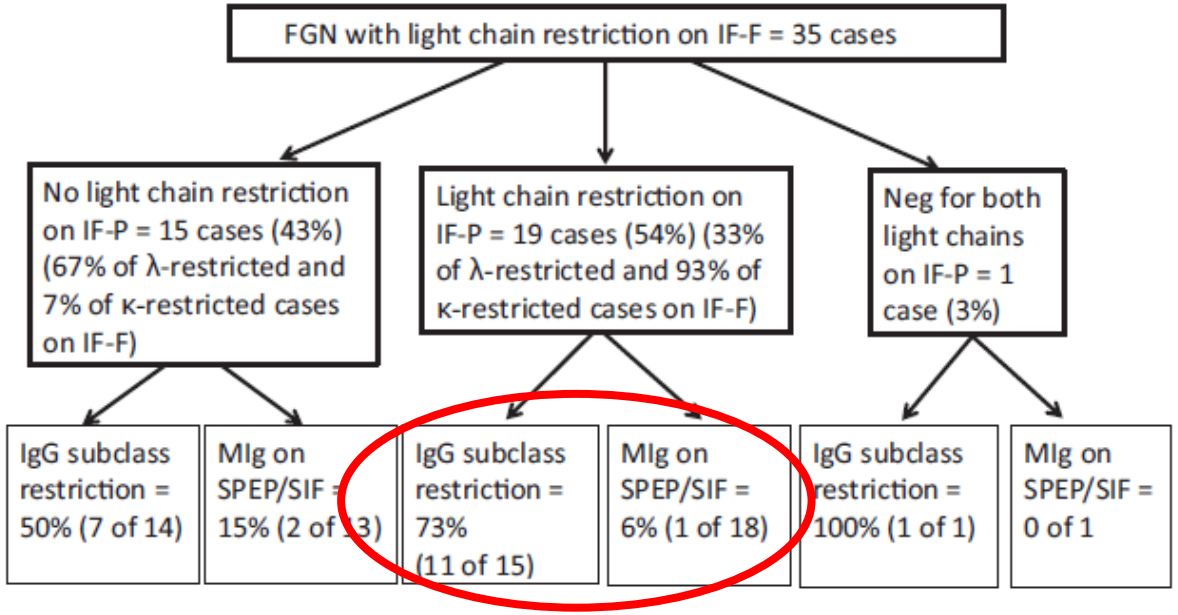

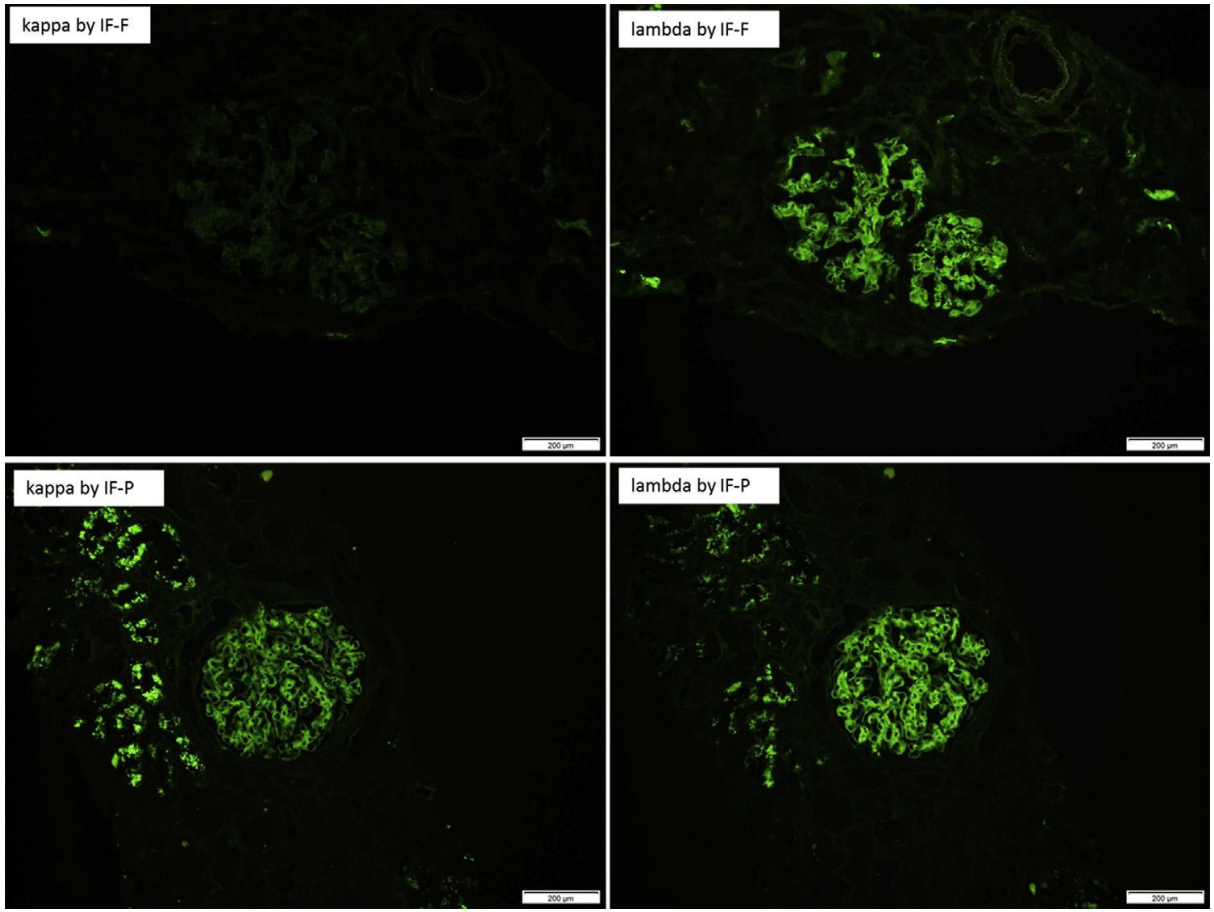

Monotypic FGN (confirmed by paraffin IF and IgG subclass restriction) accounted for **only one of 151 (0.7%)** patients with FGN encountered over 2 years

*Because the IF-F tissue in all of our cases had been placed in **Michels (Zeus) transport media before freezing**, it is possible that this phenomenon could be due to interference of the transport media with anti-λ reactivity on IF-F…….*

Said SM, et al.Kidney Int 2020; 98: 498-504

2021 Classification of MGRS-associated renal lesions

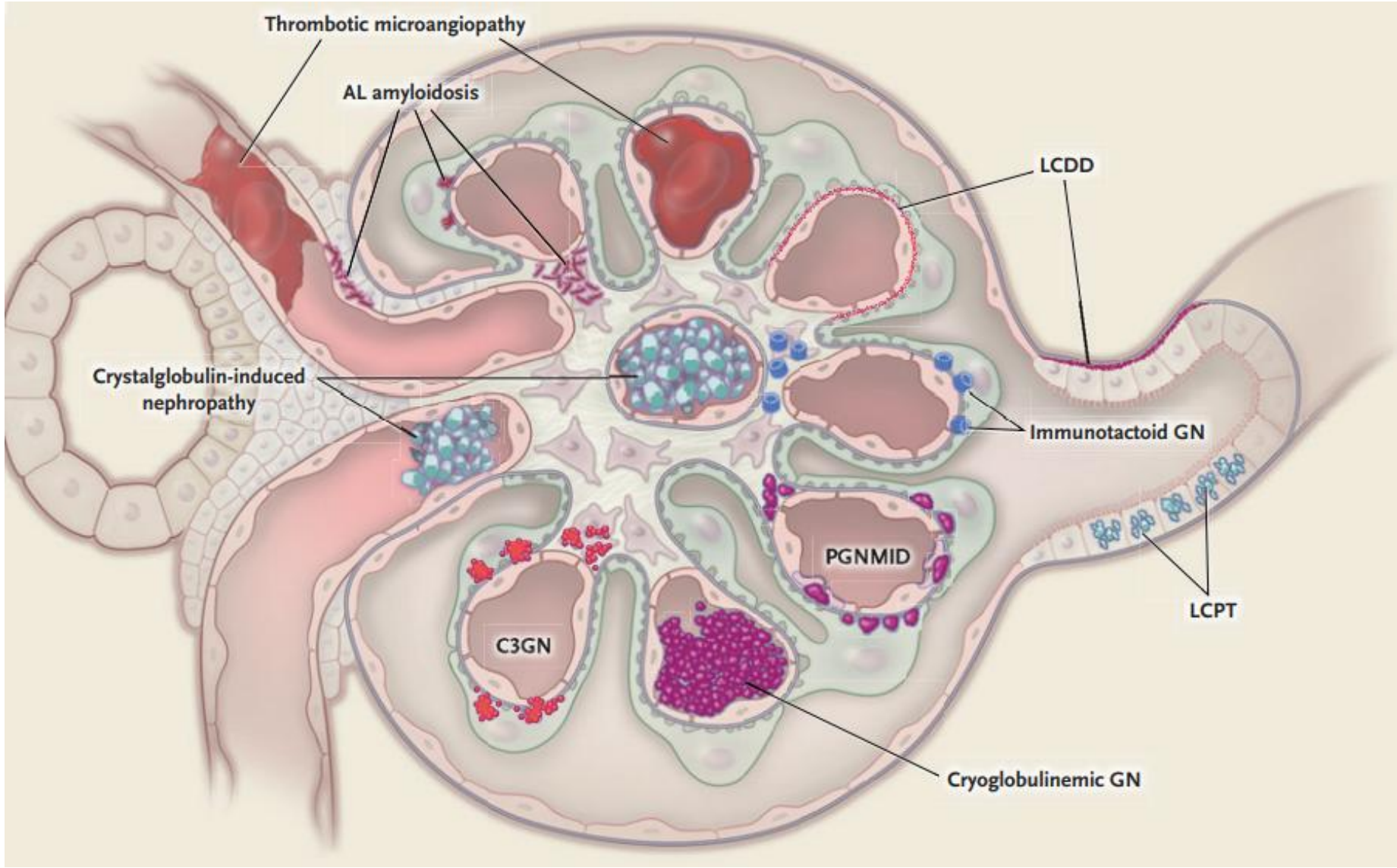

Leung N, Bridoux F, Nasr SH. N Engl J Med 2021;384:1931-41

Heavy Chain Fibrillary Glomerulonephritis

- **50 year-old man** with ESKD secondary to glomerular disease, 2 failed allografts because of disease recurrence

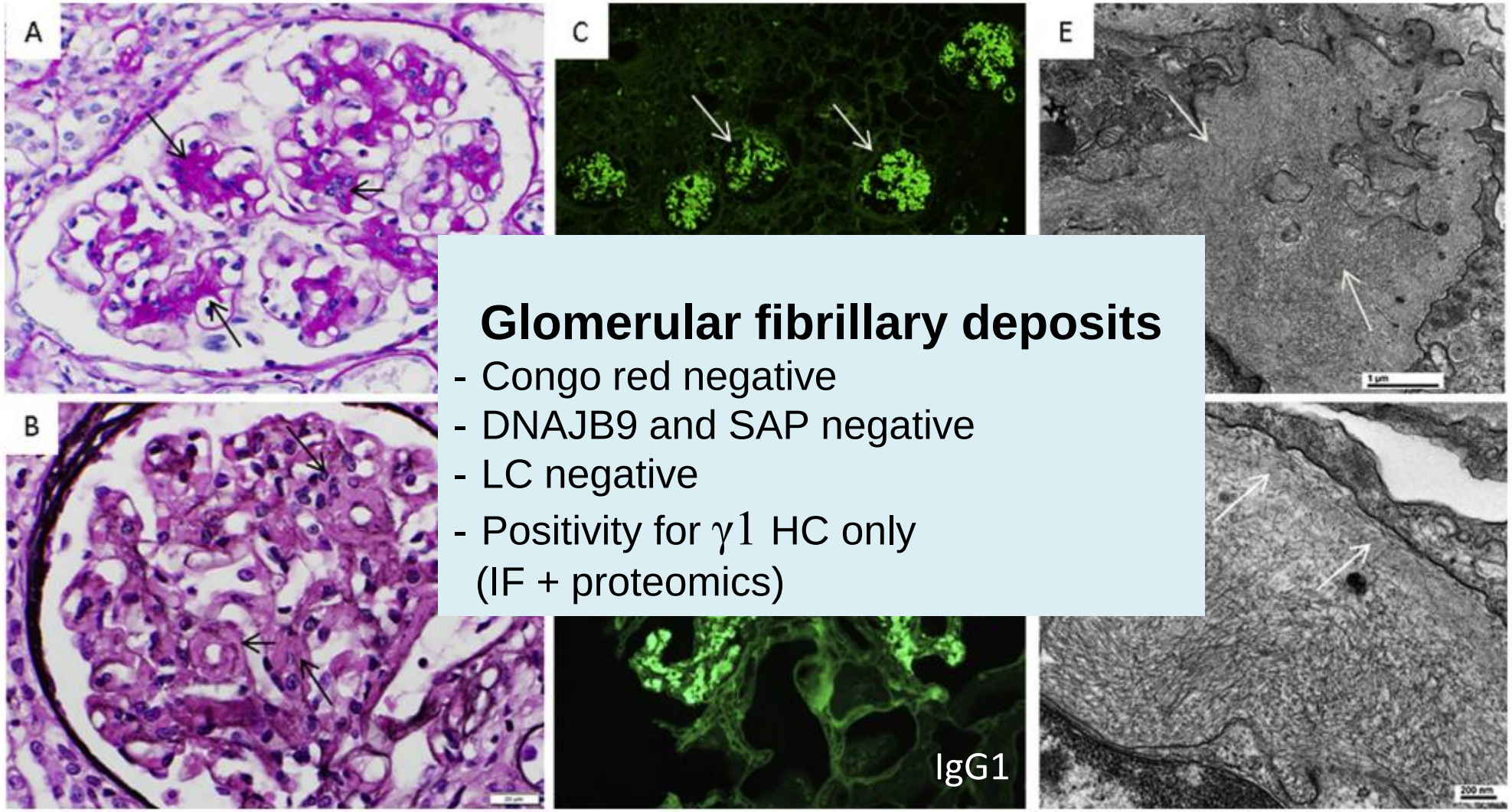

Glomerular fibrillary deposits

- Congo red negative
- DNAJB9 and SAP negative
- LC negative
- Positivity for $\gamma 1$ HC only (IF + proteomics)

Heavy Chain Fibrillary Glomerulonephritis

- **Hematologic workup :**
  - -Serum and urine IgG λ monoclonal gammopathy
  - -Bone marrow clonal plasma cell population (10%) expressing IgG and λ light chain

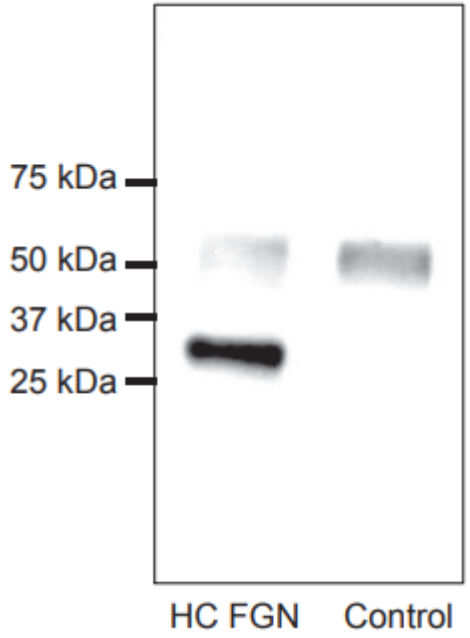

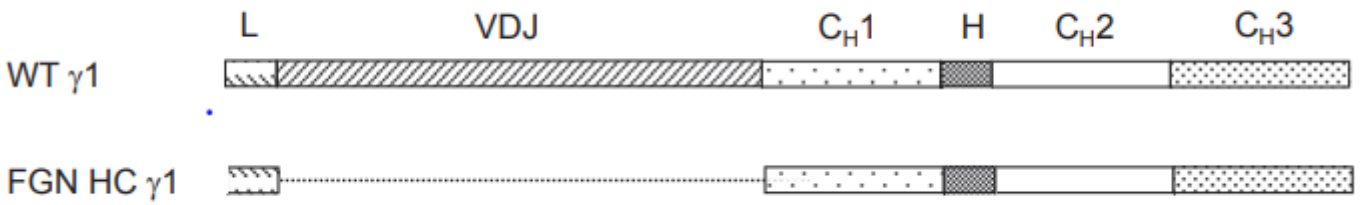

Bone marrow molecular studies
γ1 heavy chain (IGHG1*03) with complete absence of the VDJ (variable-diversity-joining) exon

Serum W.blot and immunofixation analysis:
truncated monoclonal γ1 HC (30 kDa)

Nasr SH, Sirac C, et al. Am J Kidney Dis 2019;74: 276-80

Ig-Negative DNAJB9-Associated Fibrillary GN : A Report of 9 Cases

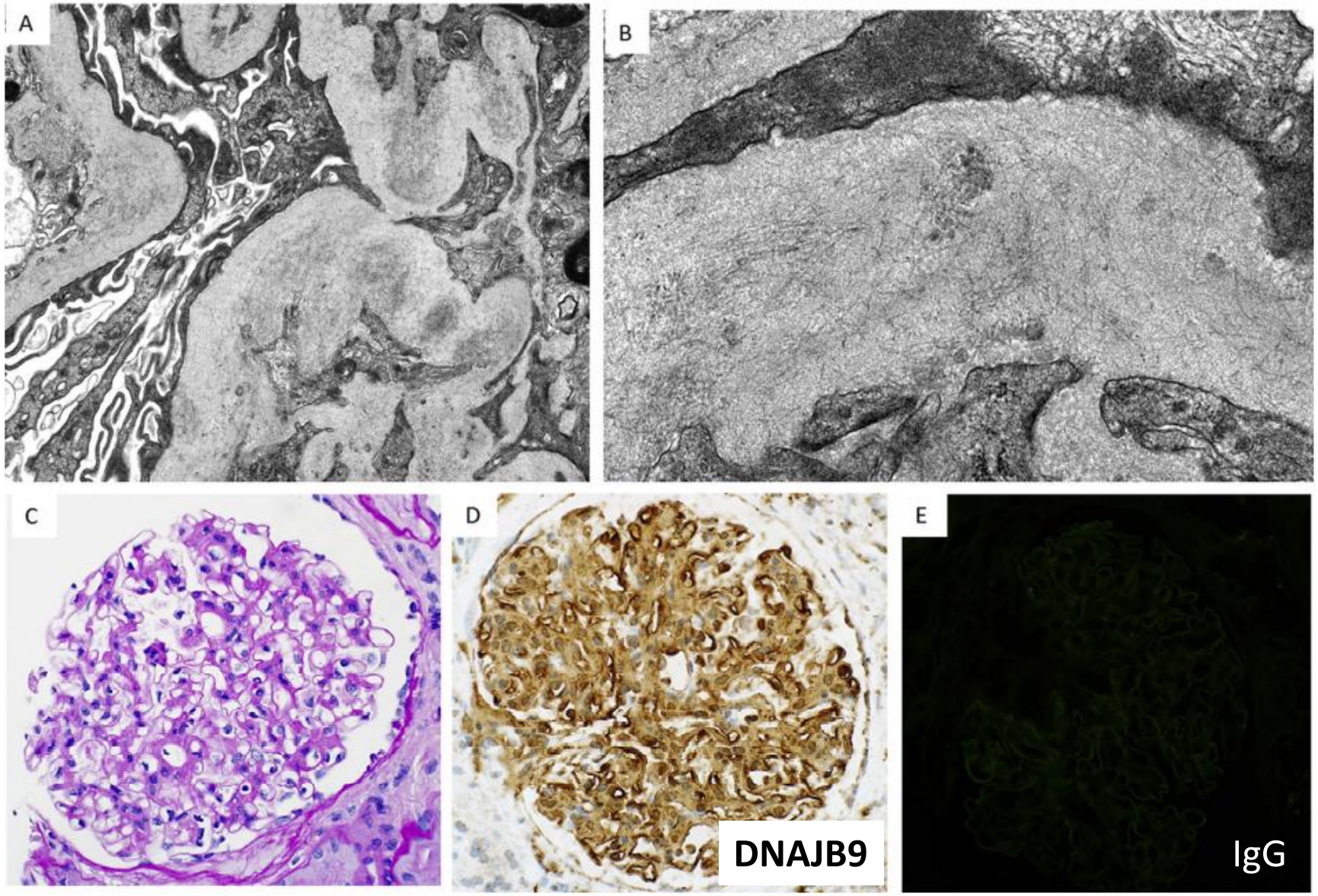

DNAJB9 (not IgG) critical for FGN fibril formation ?

In rare cases, DNAJB9 deposition does not trigger autoimmune response or triggers minimal response below the level of detection by IF antibodies ?

Nasr S, et al. AJKD 2021;77: 454-8

Congophilic Fibrillary Glomerulonephritis : A Case Series

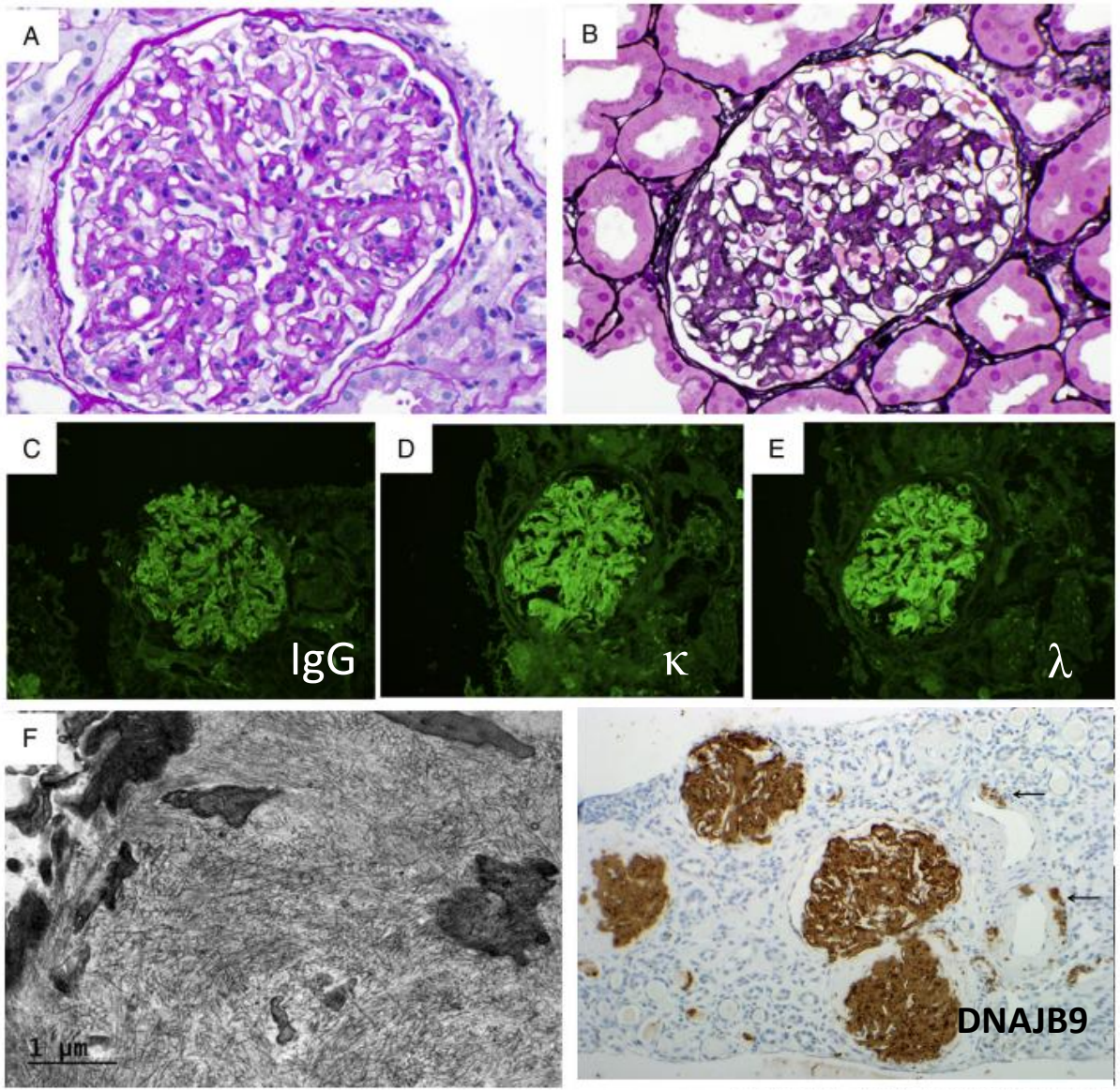

- **18 patients**
- Mean age at diagnosis : 65 years
- Concomitant monoclonal gammopathy 35%
- No patient had evidence of extrarenal amyloidosis.
- Renal manifestations: proteinuria (100%), nephrotic syndrome (47%), hematuria (78%), and chronic kidney disease (83%)
- ESKD: 31% after mean follow-up of 23 months

Alexander MP, et al. AJKD 2018; 72: 325-336

Congophilic Fibrillary Glomerulonephritis : A Case Series

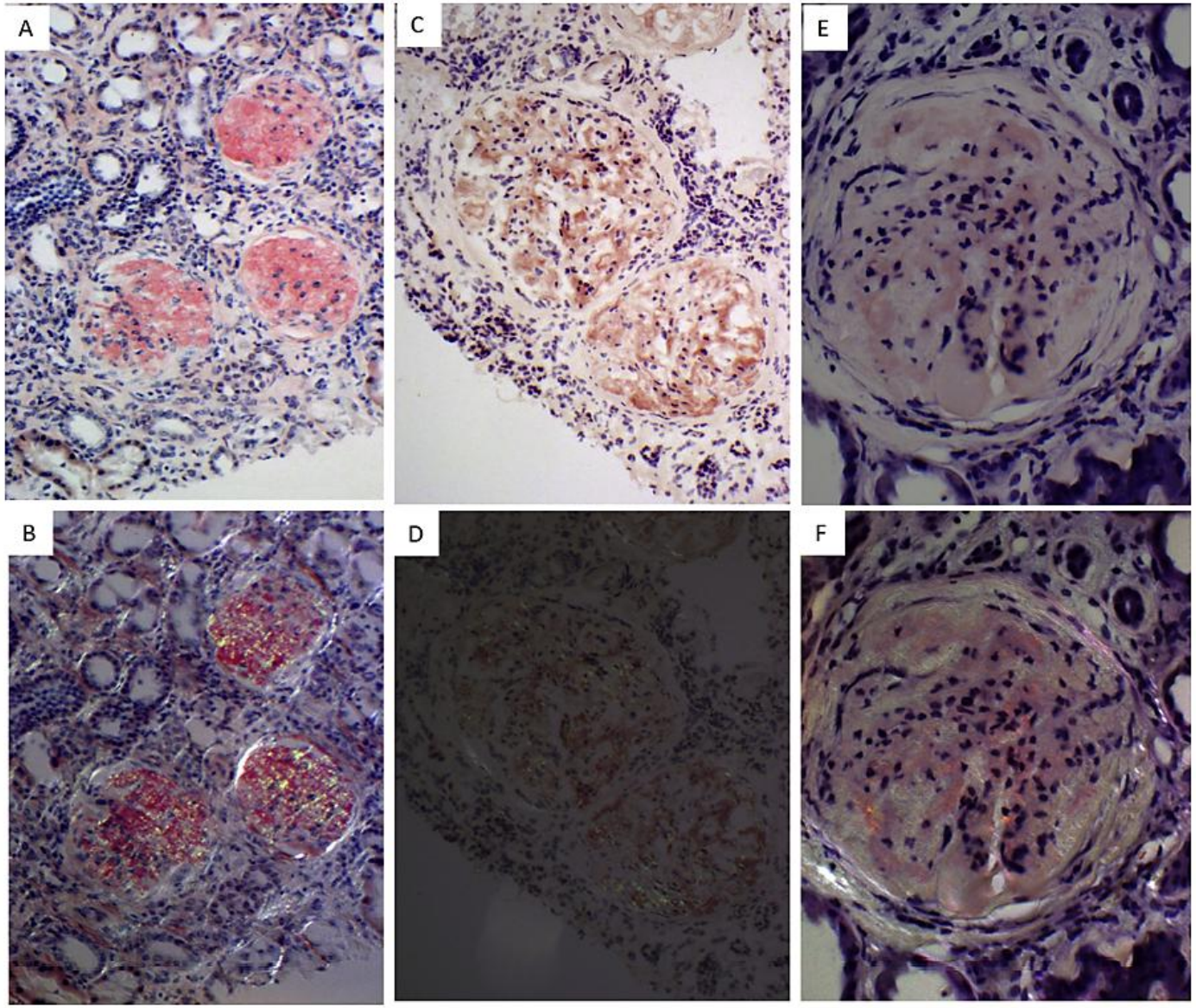

Alexander MP, et al. AJKD 2018; 72: 325-336

Proteomic Characterization of Congophilic FGN

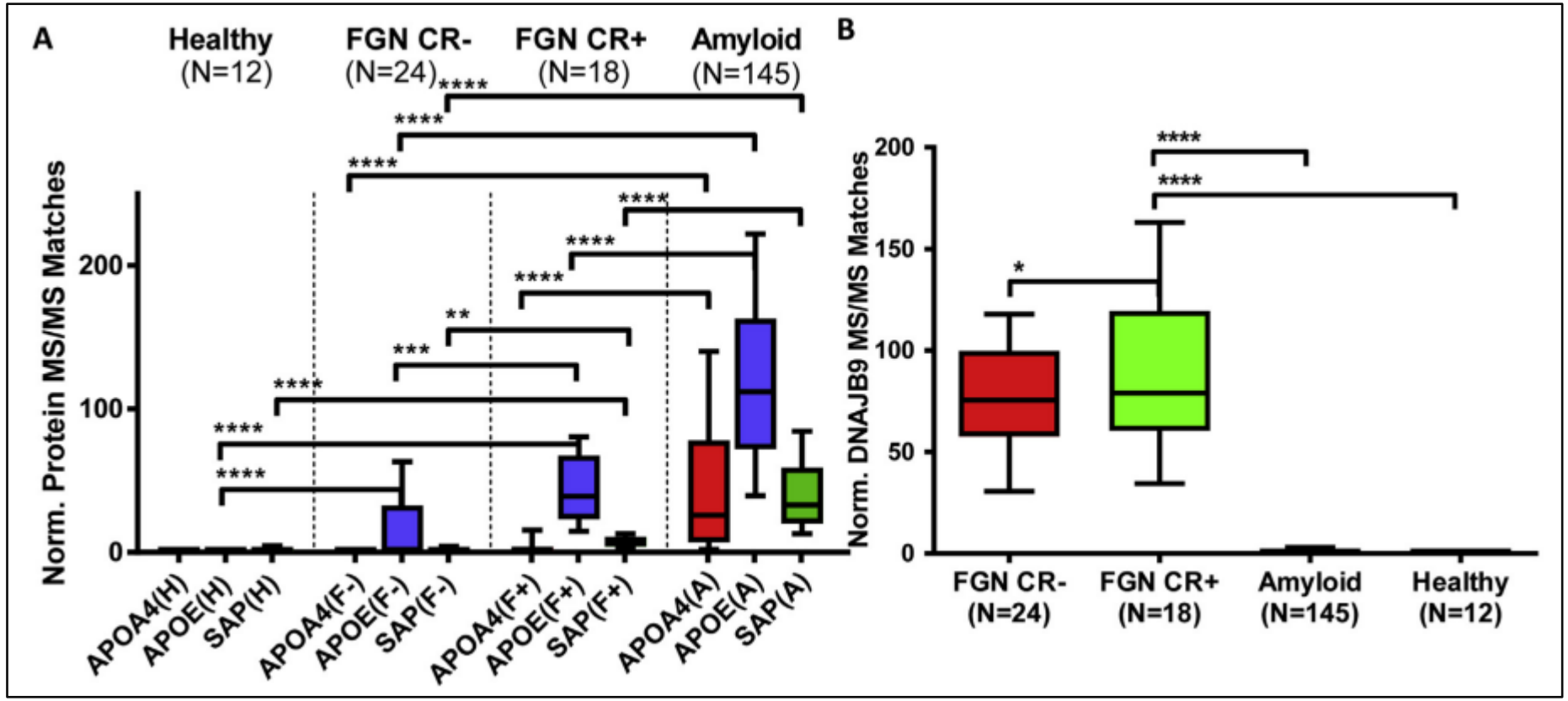

Conclusions :
Diagnostic value of combined DNAJB9 IHC + proteomics to distinguish FGN from amyloidosis
Congophilia due to increased amounts of APOE in deposits?

Alexander MP, et al. AJKD 2018; 72: 325-336

FGN : Treatment and Renal Outcomes

- Treatment of FGN is poorly defined

Study (Pts)	F-up (mo)	Treatment	Renal outcome
Rosenstock (n=61)	23	None/RASb: 64% CS /IS therapy: 36%	Renal resp.: 7% ESRD: 45% (med.: 24 mo)
Nasr (n=66)	48	None/RASb: 52% CS/IS therapy: 48%	Renal resp.: 13% PRD: 43% ESRD : 44%
Javaugue (n=27)	46	RAS blockade: 52% CS/IS therapy: 48%	Renal resp. : 30% PRD: 22% ESRD: 48% (med.: 44 mo)

- Rituximab therapy: renal response in 5/7 patients (MesGN / MGN and eGFR >70 ml/min/1.73m^2)

Javaugue V et al. Am J Kidney Dis 2013; 62:679-90

Rosenstock JL, et al. Kidney Int 2003; 63: 1450-61
Nasr SH et al. Clin J Am Soc Nephrol 2011; 6: 775-84

FGN : Rituximab Therapy

- Variable efficacy :
  - Complete response reported in few patients with normal renal function
  - Partial response (stabilization of kidney function) : ~ 30%

- Determinants of response to rituximab :
  - Time from kidney biopsy to rituximab treatment :
    4.3 months (responders) *vs* 8 months (NR)
  - Baseline eGFR :
    72 mL/min/1.73 m^2 (responders) *vs* 38 mL/min/1.73 m^2 (NR)

- Monitoring circulating CD19+ B-cells :
  - Possible renal relapse with B-cell reconstitution

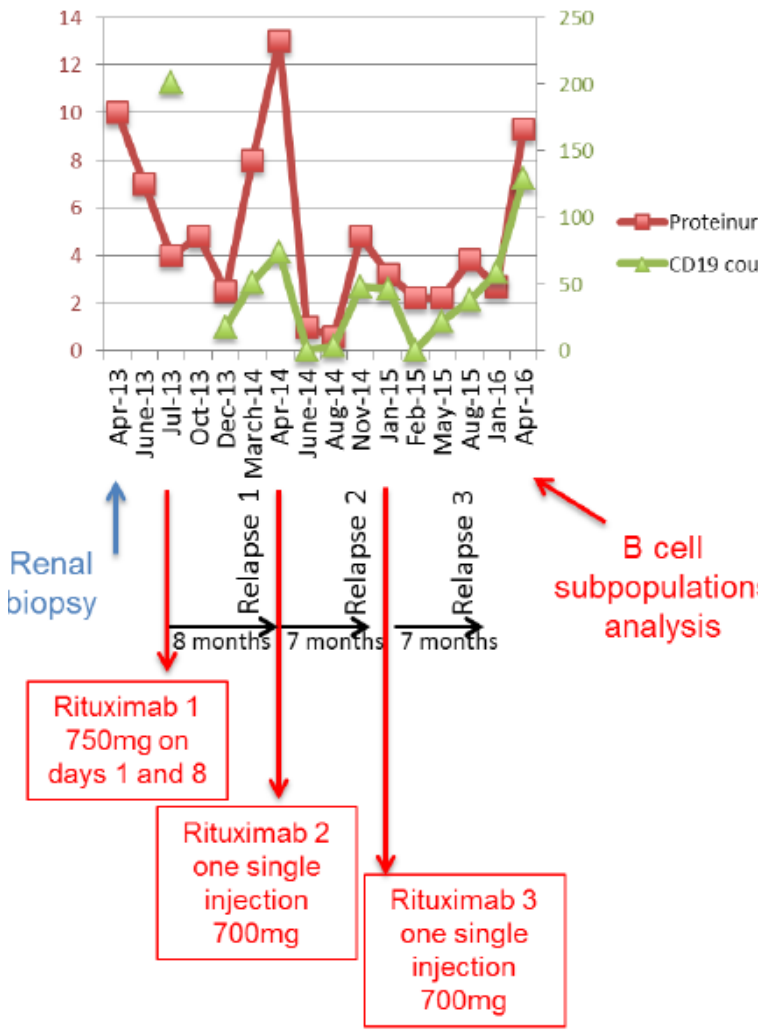

Hogan J et al. Nephrol Dial Transplant 2014; 29: 1925-31
Leibler C, et al. J Clin Med 2018; 7: 430
Andeen NK, et al. Clin J Am Soc Nephrol. 2019 6;14:1741-50

FGN : Rituximab Therapy

- Open-label phase II study in 11 patients (Mayo Clinic)
  - Rituximab 1g x 2, 2 weeks apart, identical retreatment 6 months later

  - At 12 months :
    No change in creatinine clearance *vs* baseline (47.7 vs. 43.7 ml/min, p=0.21)
    Proteinuria decreased from 3.8 to 2.6 g/day (p=0.068)
    3 patients had significant reduction of proteinuria (≥ 50%)
    No change in serum DNAJB9 levels

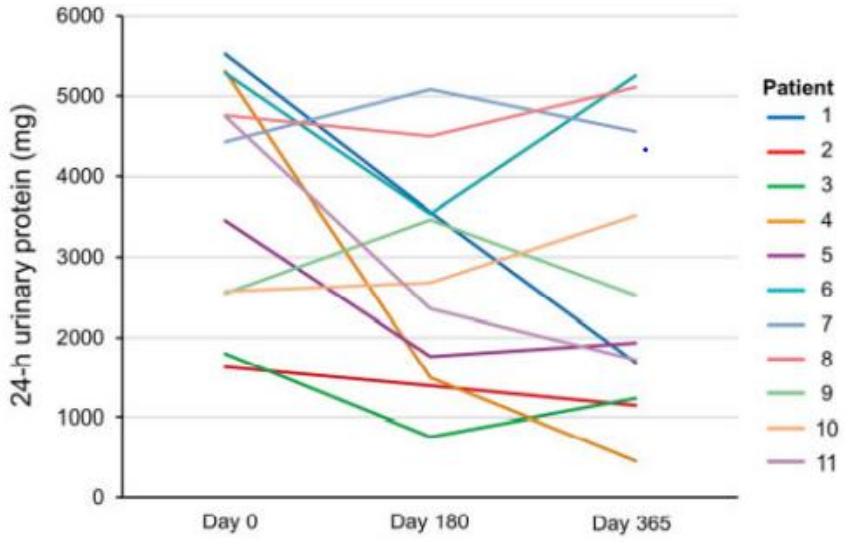

FIGURE 2: Change in proteinuria over time.

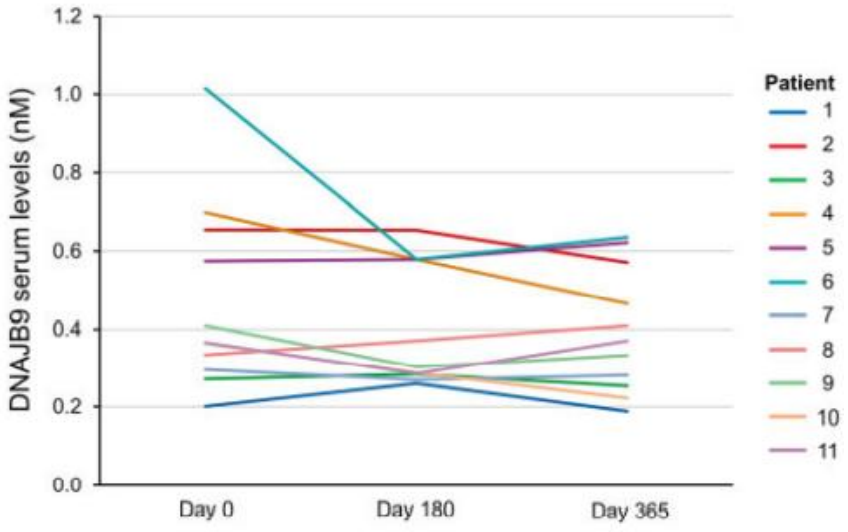

FIGURE 4: DNAJB9 serum levels following treatment with rituximab.

Erickson SB, et al
NDT 2021;36:104-10

FGN : Renal and Patient Outcomes

- Median renal survival : 24 to 48 months

  Nasr SH et al. Clin J Am Soc Nephrol 2011; 6: 775-84
  Andeen NK, et al. Clin J Am Soc Nephrol. 2019 6;14:1741-50

- Factors associated with ESKD/death :
  - Male sex (aHR 3.82, [95% CI, 1.97- 7.37])
  - eGFR : <30 ml/min/1.73 m^2 (HR 8.02, [95% CI, 1.85 - 34.75])
    30-45 ml/min/1.73 m^2 (HR 6.44 [95% CI, 1.38 - 29.99])

- Rituximab therapy :
  - Lower risk of progression to ESKD (HR 0.43; P=0.008)

  Andeen NK, et al. Clin J Am Soc Nephrol. 2019 6;14:1741-50

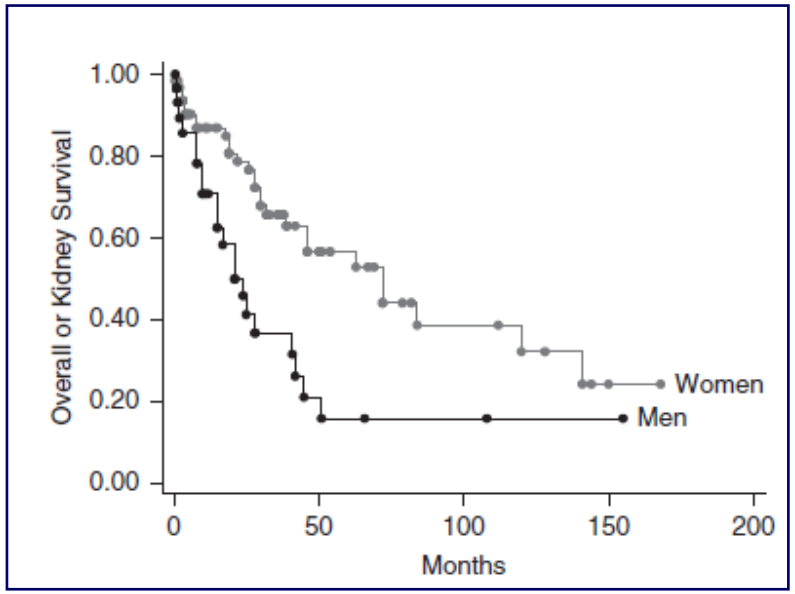

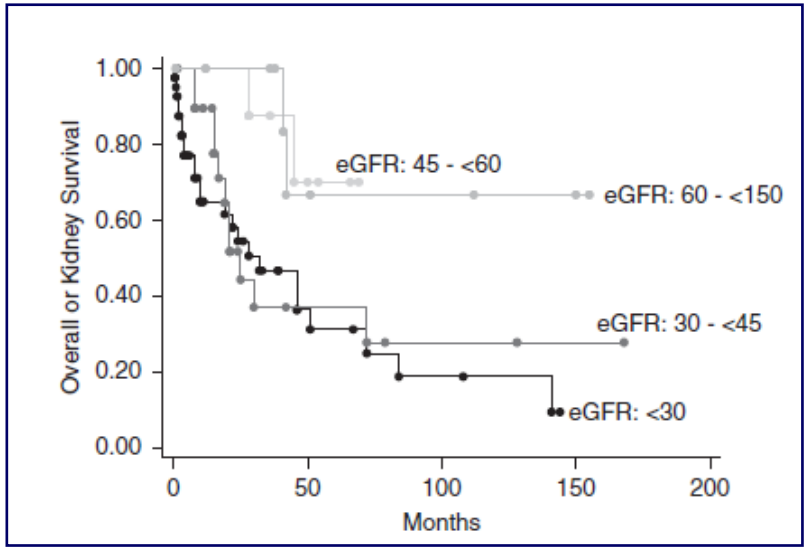

FGN : Histological Patterns and Outcomes

- Histological findings associated with renal survival
  - Interstitial fibrosis / global glomerulosclerosis
  - Histologic subtype : MPGN vs Membranous GN or Mesangial GN
  - Extracapillary proliferation

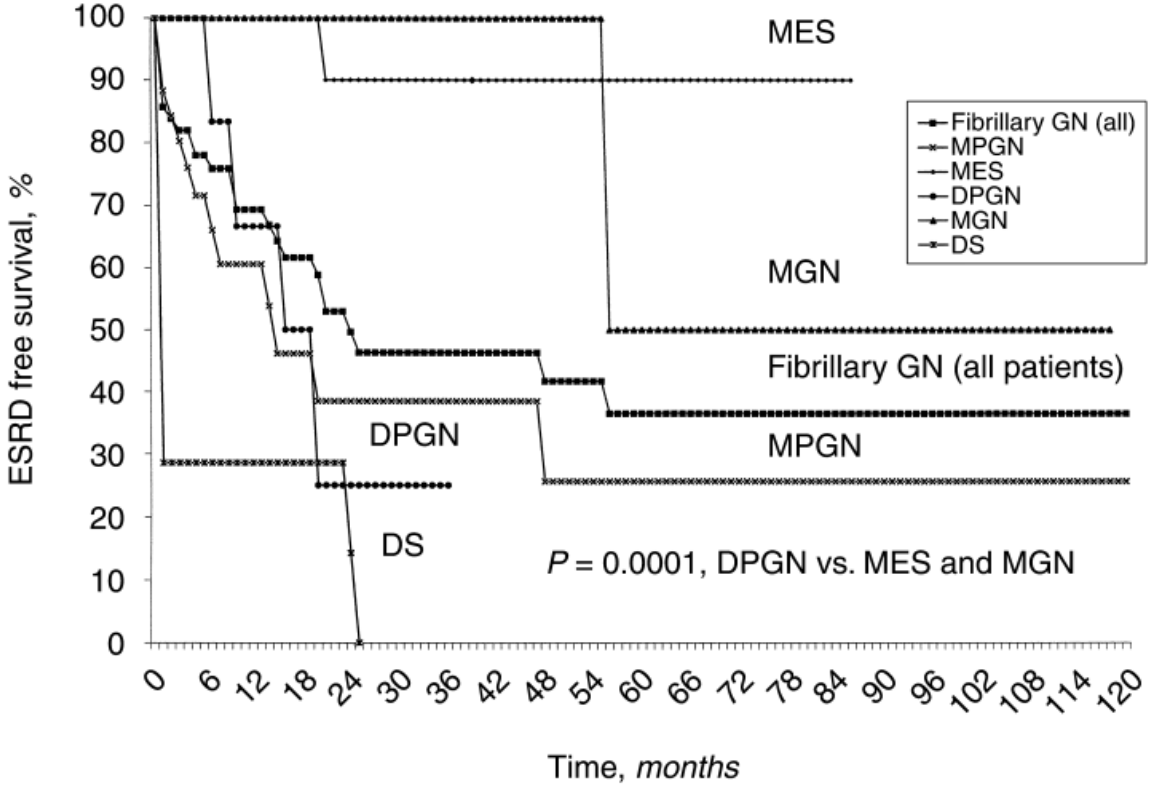

Rosenstock JL, et al. Kidney Int 2003; 63: 1450-61

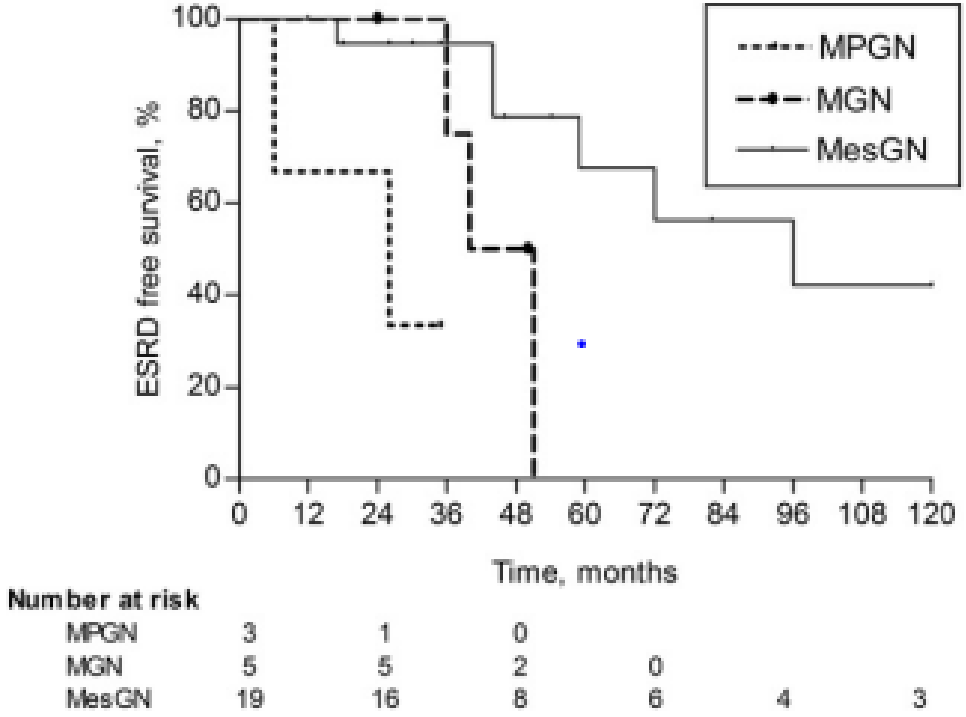

Javaugue V, et al. Am J Kidney Dis 2013; 62:679-90

FGN : Prognosis of Diffuse Crescentic Lesions

- Crescents involving ≥50% of glomeruli (2.7% of FGN biopsies)

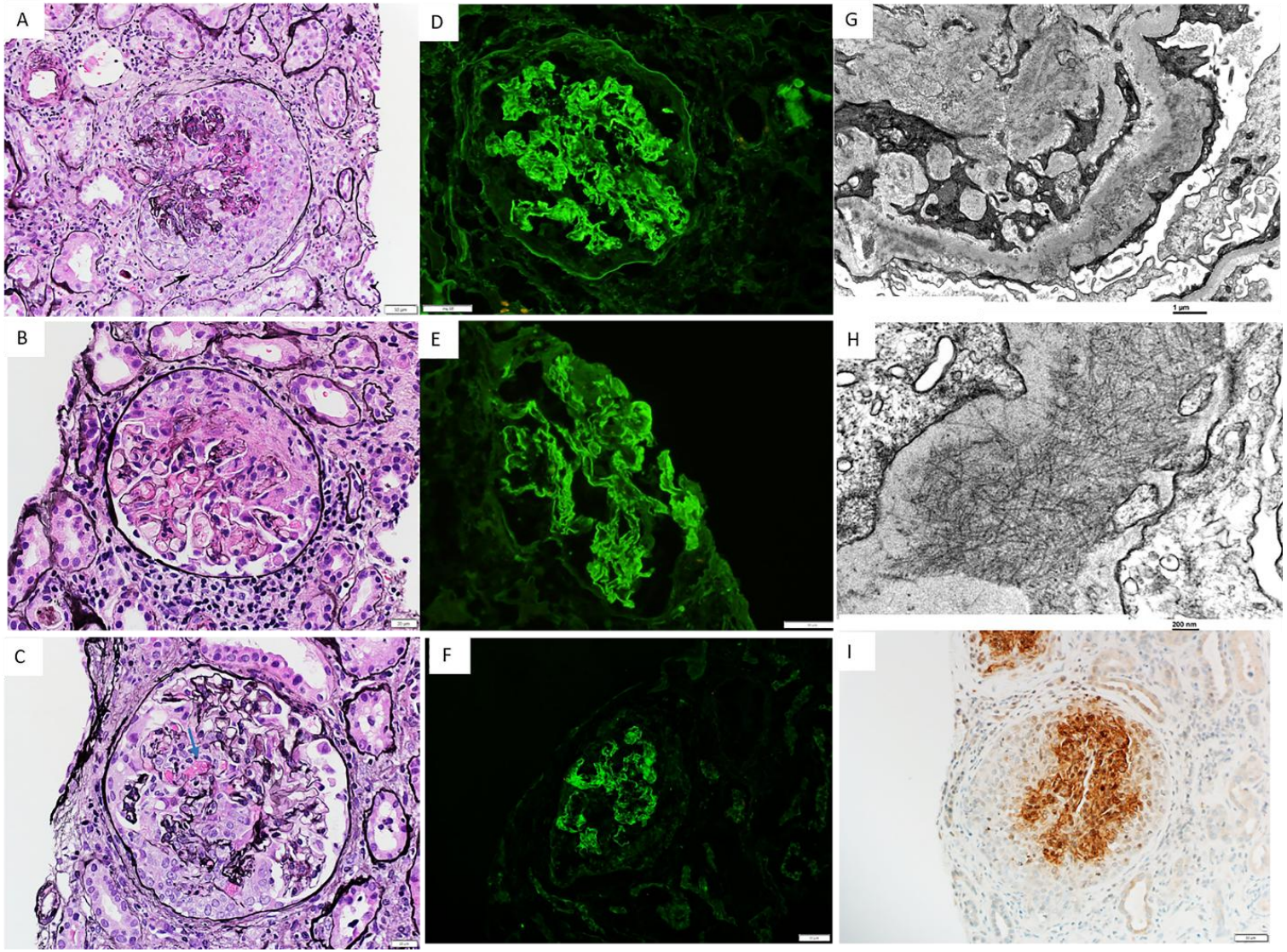

- 21 patients
- RPGN (100%)
- HD at diagnosis : 40%
- ANCA positivity : 19%
- Anti-GBM positivity : n=1
- IS therapy (CS/rituximab/CYC) : n=19
- ESKD : 82% (median 2 months from biopsy)

Javaugue V, Nasr SH, et al. In preparation

FGN : Renal Transplantation

- Patient and allograft survival similar to standard population
  - 10-year patient and allograft survival rates : 100% and 67% (n =13)

Mallet A, et al. Am J Nephrol 2015; 42: 177-84

- Low rate of recurrence on the allograft
  - 14 patients transplanted for DNAJB9 positive FGN (1996–2016)
  - Protocol biopsies at 4, 12, 24, 60 and 120 mo post-Tx
  - Median follow-up 5.7 years

  - Recurrent disease: 3 patients (21%)
  - Median time to recurrence : 10.2 years
    5 yrs (n=1) and 10 (n=2) yrs post-transplantation
  - Median proteinuria 243 mg/day, median GFR 56 ml/min

El Ters M, et al. Am J Kidney Dis. 2020;76:500-10

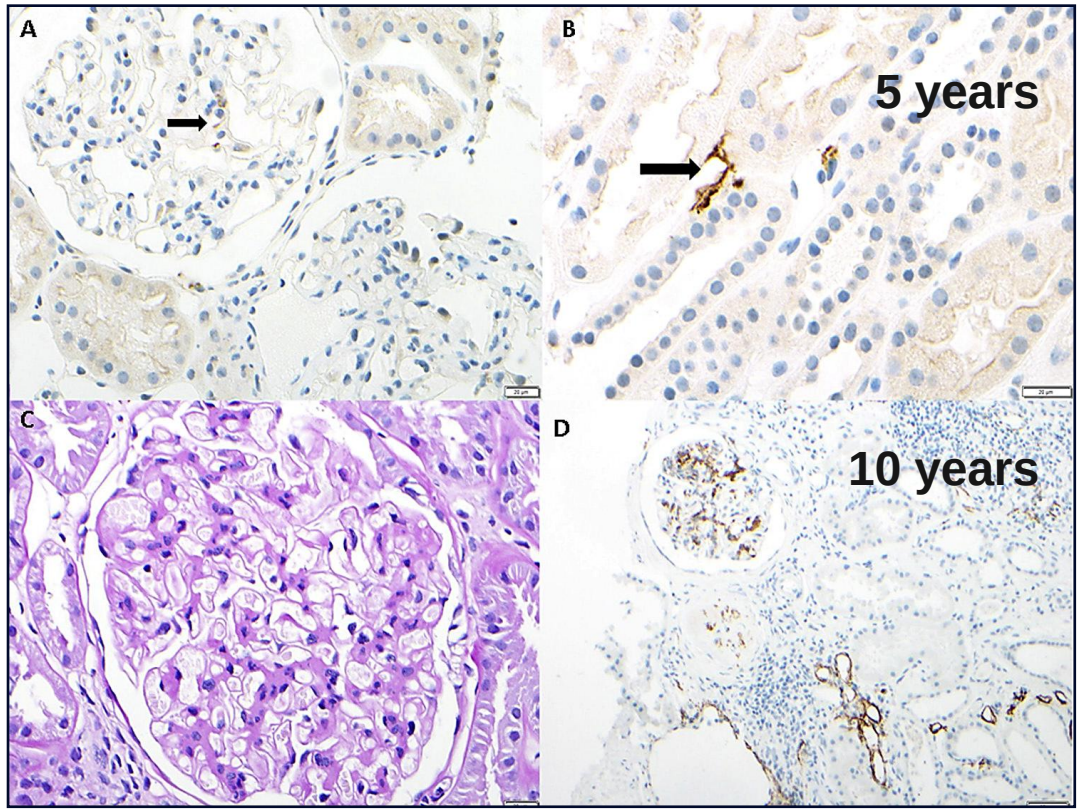

Fibrillary Glomerulonephritis : Conclusions

- Rare glomerular disorder but with underestimated frequency
- IgG deposits almost always polyclonal : FGN does not belong to the MGRS spectrum
- DNAJB9 : specific tissue biomarker by IHC and IF
- Pathogenesis still unclear
  - DNAJB9 : autoantigen or recognizing aggregation-prone motifs on misfolded IgG4?
  - Mechanisms of fibril formation ?
  - Frequent association with auto-immune diseases, solid cancers and viral infection
  - Genetic background ?

Fibrillary Glomerulonephritis : Conclusions

- Renal prognosis associated with :
  - Proliferative glomerular lesions
  - GFR value at diagnosis
  - Time form diagnosis to treatment initiation
- Treatment remains poorly defined
  - Relative efficacy of rituximab in patients with MGN / MN patterns and preserved kidney function
  - Rapid progression to ESKD if MPGN / diffuse crescentic patterns despite IS therapy
  - Anti-CD20 based regimens (+/- cyclophosphamide, belimumab, anti-CD38 mAbs) to be evaluated
- Favorable prognosis after kidney transplantation with low recurrence rate

Acknowledgements

- **Departments of Nephrology and Pathology, University Hospital Poitiers, France :**

  Guy Touchard, Estelle Desport, Vincent Javaugue, Elise Michelon

  Jean-Michel Goujon, Sihem Kaaki, Alexia Rinsant, Cécile Ory

- **Department of Hematology, University Hospital Limoges, France :**

  Arnaud Jaccard, David Lavergne

- **CNRS UMR 7276 – INSERM U 1262, Limoges :**

  Christophe Sirac, Michel Cogné, Sébastien Bender

- **Department of Hematology and Immunology, Saint Louis Hospital, Paris :**

  Jean Paul Fermand

- **Departments of Nephrology and Pathology, Mayo Clinic, Rochester, USA**

  Nelson Leung, Samih Nasr

Fibrillary Glomerulonephritis : Associated Conditions

Autoimmune disease	Malignant neoplasm	Viral infection
Systemic lupus erythematosus[10,11,15]	*Solid*	Hepatitis C[1,10–12,15,21,28–31]
Crohn disease[28]	Thyroid carcinoma[10,15]	Hepatitis B[12]
Hashimoto thyroiditis[21]	Hepatic carcinoma[10,32,33]	HIV[12,34,35]
Graves disease[10,21]	Colon carcinoma[10,11,21]	
Sjögren syndrome[10,28,36,37]	Gastric carcinoma[38]	
Psoriasis[21]	Breast carcinoma[10,12,15,28]	
Rheumatoid arthritis[11,15,20,21]	Lung carcinoma[11,12,28]	
Ankylosing spondylitis[10,15]	Uterine carcinoma[10]	
Idiopathic thrombocytopenic purpura[10,15]	Prostate carcinoma[10,15]	
Autoimmune hemolytic anemia[21,39]	Renal cell carcinoma[10,11]	
Hypocomplementemic urticarial vasculitis[21]	Bladder carcinoma[28]	
Primary biliary cirrhosis[10,15,39]	Squamous cell carcinoma of skin[12]	
Primary sclerosing cholangitis[15]	Melanoma[10]	
Sarcoidosis[15]	*Hematologic*	
Limited scleroderma[40]	Multiple myeloma[10]	
	Chronic myelomonocytic leukemia[10]	
	Hodgkin lymphoma[15]	
	Non-Hodgkin lymphoma[20]	
	T-cell lymphoma[15,41]	
	Myeloproliferative neoplasm[11,15,20,39]	

Nasr SH, Fogo AB. Kidney Int. 2019;96:581-92