Donor derived fungal infections in transplant patients

Olivier Lortholary
Centre d'Infectiologie Necker-Pasteur
Université Paris Descartes, Hôpital Necker Enfants malades,
IHU Imagine &
Centre National de Référence Mycologie & Antifongiques,
Unité de Mycologie Moléculaire, CNRS URA3012
Institut Pasteur, Paris, France.

Evolution of Organ Transplant in France

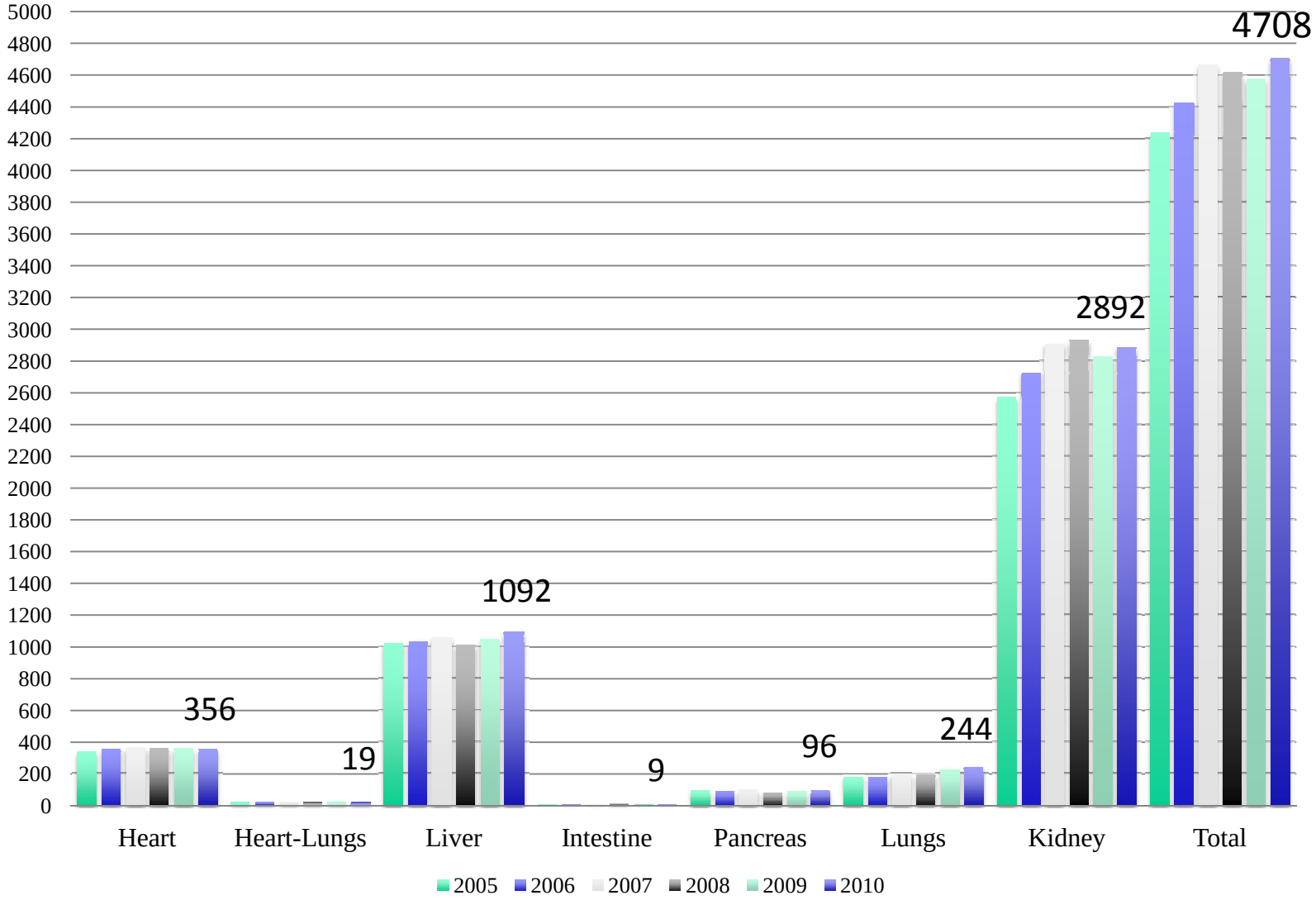

Annual report of the French Agency of Biomedicine

Contamination/Transmission of fungi (1)

- Rare but potentially severe for both graft itself and/or recipient
- Early infections in recipients

- How a graft can be contaminated :
  - Infected donor:
    - Acute unrecognized/diagnosed infection at the time of sampling
    - Latent tissular infection
  - Organ contamination at the time of sampling/transportation
    - Digestive leakage and the preservation fluid contaminated
    - Transplant tourism (hygiene……)

Contamination/Transmission of fungi (2)

- Transplantation D+/R- known before procedure (endemic mycoses):
  - Initiation of prophylactic measures, appropriate follow-up
- Sometimes, D+ status discovered rapidly after transplant procedure before any manifestation in the recipient (Candida)
- Rarely, transmission discovered after ≥ 1 recipients from the same donor have developed the IFI (molds)

Criteria for classification of donor-derived fungal infections

Proven: This requires **clear and incontrovertible evidence of donor origin of infection in at least one recipient.**

Mycologic and/or histopathologic evidence of fungal infection in the donor.

Mycologic and/or histopathologic evidence of the same organism in at least one recipient of the same donor.

When relevant, demonstration of clonally or molecularly identical isolates both in the donor and at least one recipient.

Probable: This includes **strong evidence suggesting but not proving donor-origin of fungal infection transmission.**

Laboratory and/or histopathologic evidence of infection in more than one recipient of the same donor.

Serologic evidence of active infection in the donor in the absence or non-availability of laboratory isolation or histopathologic evidence of infection. The serologic evidence of infection as applicable is discussed under specific fungi.

Proven and probable events are considered confirmed transmissions.

Possible: This category may be used for instances where data are insufficient to fulfill aforementioned criteria for proven or probable infection; however, donor origin of transmission cannot be reasonably excluded.

Guidelines of the American Society of Transplantation, Infectious Diseases Community of Practice Singh et al. AJT In press

IFI in SOT recipients:

TRANSNET data

1208 IFI in 1063 organ transplant recipients

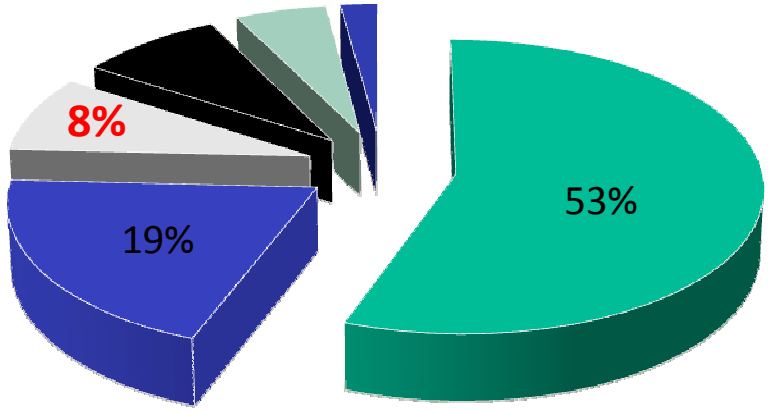

Median time post-transplant

- Candidiasis ↔ 103 d
- Aspergillosis ↔ 184 d
- Cryptococcosis ↔ 575 d
- Non-Asp molds
- Endemic fungi
- Zygomycosis

Pappas, CID 2010

Early IFI/unsual sites should suggest graft-transmitted IFI

1st situation : donor known to have IFI

- Invasive fungal infection: sampling contraindicated:
  - Candidiasis (urinary?/invasive)
  - Cryptococcosis
  - Aspergillosis
  - Mucormycosis…. others
- Silent IFI:
  - Histoplasmosis & Coccidioidomycosis
    - Not screened before grafting (Europe)
    - And if yes?: contraindication if active infection or treatment in recipient

Unrecognized pretransplant or donor derived cryptococcosis in SOT

Sun et al. CID, 2010

- Multicenter cohort : 175 (SOT) recipients with cryptococcosis
- Very-early and late-onset cryptococcosis were defined as disease occurring ≤30 days or >30 days post-transplant, respectively.
- Very-early onset disease :
  - 5% ; mean of 5.7 days post-transplant.
  - More frequently liver transplant recipients
  - More frequent unusual locations [transplanted allograft and surgical fossa/site (55.6% vs. 7.2%, p<.0001)]
  - May have unrecognized pre-transplant or…donor-derived cryptococcosis.

Graft transmitted cryptococcosis in the US

Baddley et al. CID 2011; Lyon et al. unpublished

	Alleles						
Locus	CAP59	GPD1	IGS1	LAC1	PLB1	SOD1	URA5
Allele Length	501	489	725	471	533	536	637
Patient 1 blood	8	10	15	8	12	3	11
Patient 2 blood	8	10	15	8	12	3	11
Patient 3 blood	8	10	15	8	12	3	11
Patient 3 CSF	8	10	15	8	12	3	11

MLST similarities of *C. neoformans* isolates from 3 geographically distant SOT recipients from the same donor

Screen potential donor with unexplained meningoencephalitis

No case due to *C. gattii* reported so far

2012 AST classification of donor-derived cryptococcosis [Singh, AJT in press]

C. neoformans infection pathogenesis during SOT

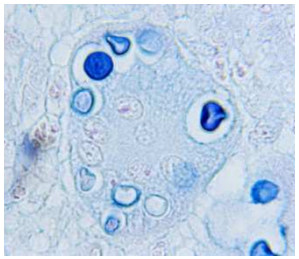

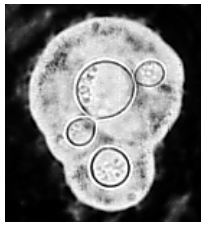

Environment

?

LUNGS
(Alveolar Mphages)

SKIN

cn

GRAFT

Latency (CD4/Th1 cytok)

Immune deficiency

Blood (PBMC)

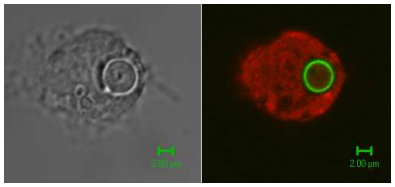

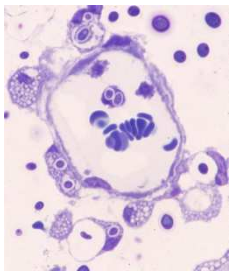

CNS Organs

PRIMARY INF?

REACTIVATION?

Mold infections acquired through unrecognized infections in the donor

- Donor (liver transplanted pt) without autopsy abnormalities with tracheal secretions growing *A. fumigatus*
  - Kidney recipients: 3 weeks post transplantation:
    - Fever & urine culture + *A. fumigatus* & renal abscesses
    - Detransplantation
  - Cardiac recipient: 3 months after transplantation:
    - Endocarditis with skin and ocular dissemination

- Donor (heart transplant pt) with unrecognized IA
  - Similar transmission to x recipients who developed IA ± death
- Transmission of *Scedosporium apiospermum*

Keating, Chest 1996; Mueller TID 2010; van der Vliet Br J Surg 1980

Underlying diseases during 169 cases of healthcare-related mucormycosis

Rammaert, CID 2012

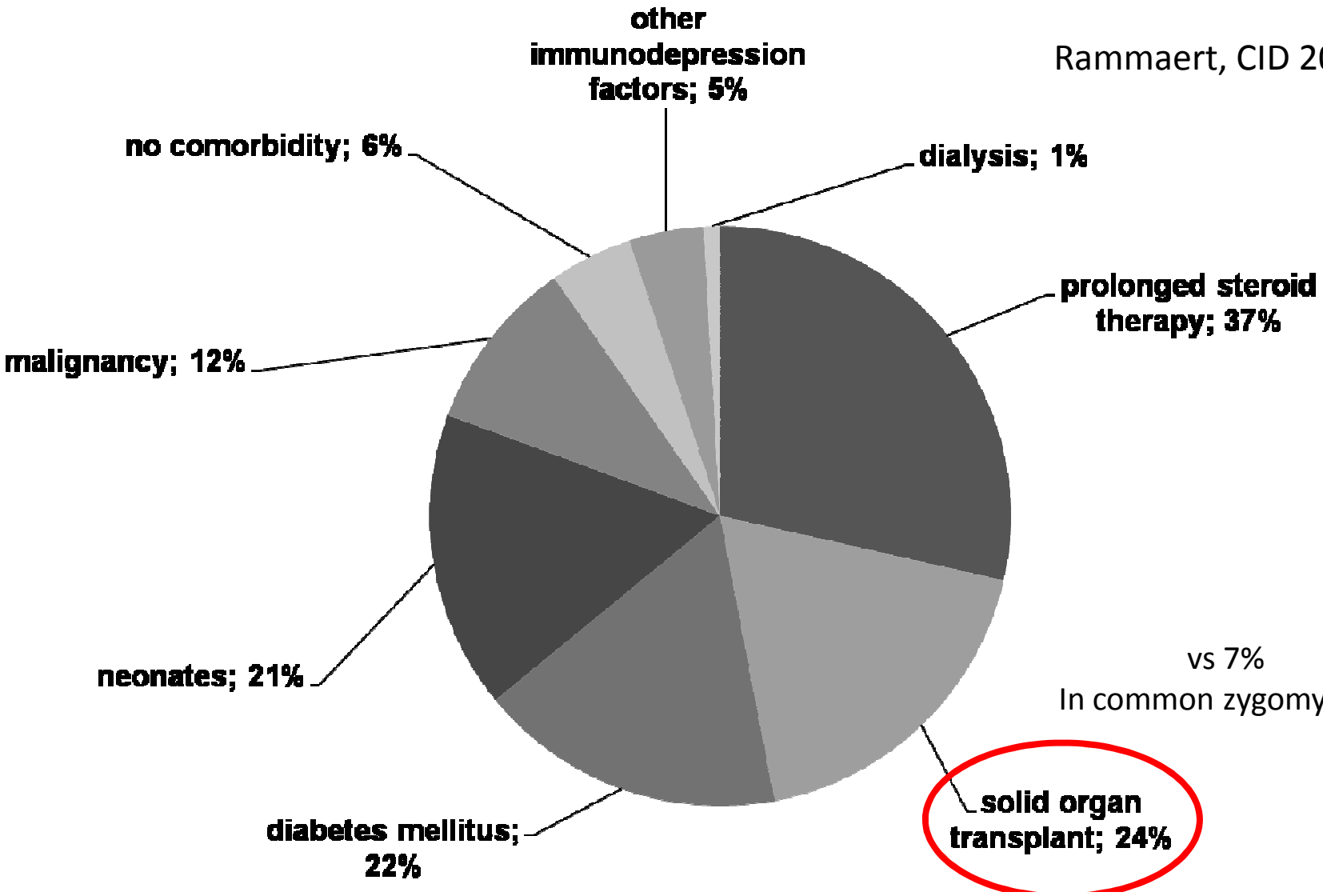

vs 7%
In common zygomycosis

Clinical sites involved during healthcare-related mucormycosis

Rammaert, CID 2012

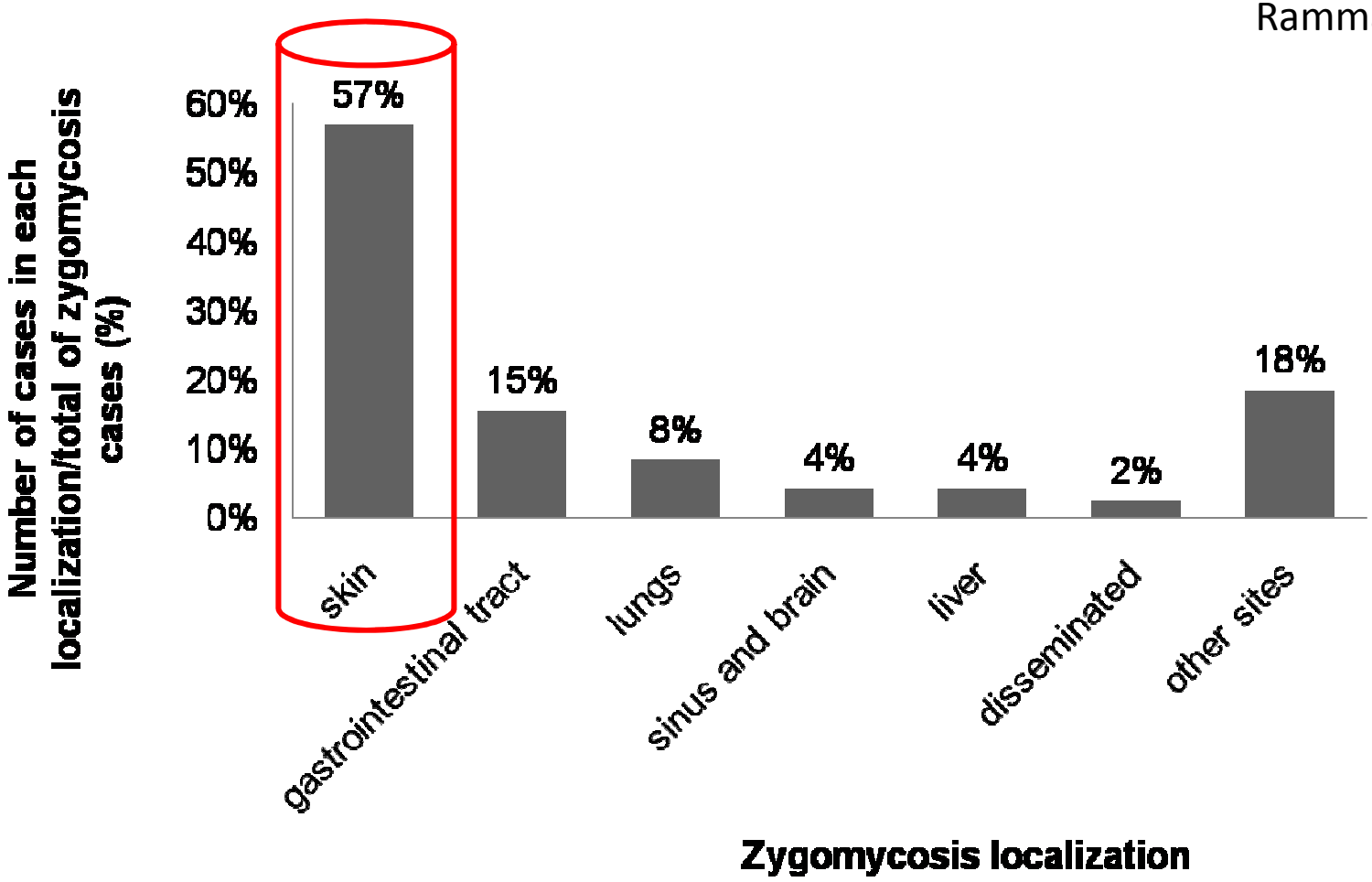

Medical procedures as a source of mucormycosis (Rammaert, CID 2012)

GRAFT ! : 14% of healthcare related mucormycosis

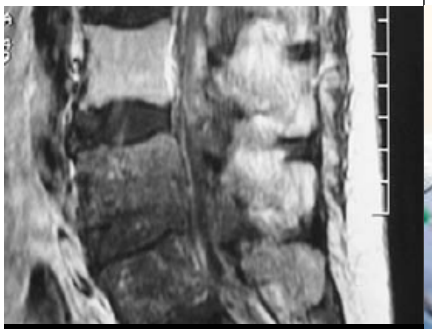

Chen F, Eur spine J 2006

Filamentous IFI and renal transplant tourism

- ✓ 19 extrapulmonary/disseminated episodes in 17 pts:
  - *Aspergillus* spp: 64%
  - *Mucorales*: 26%
  - *Rhinocladiella mackenziei* & *P. boydii*: 10%
- Allograft infection: 35%
- Graft loss : 76%
- Overall mortality: 59%
- All acquired in Asia/Middle East

Shoham Transpl Infect Dis 2010

Histoplasmosis and SOT

- 0.1-0.5% of SOT in endemic areas
- Primary-infection in SOT= travel to endemic area!
- Reactivation+++ : median 11 months PT (1.2 - 90 mo) [Freifeld, TID 2005]
- Graft transmitted : estimation of 5% of SOT-associated histoplasmosis in the USA (2012)
  - Local infection after lung transplantation (Shah; J Heart Lung Transplant. 2007

raft transmitted histoplasmosis

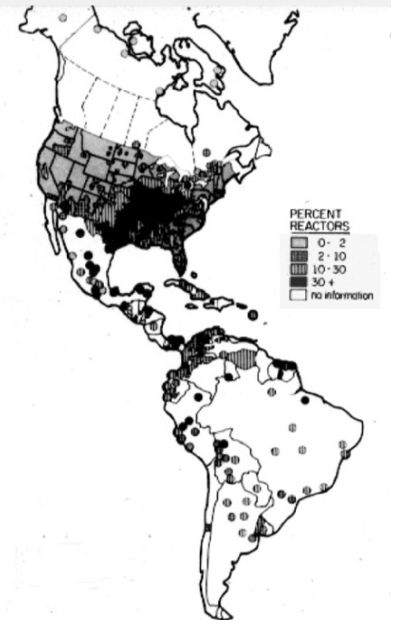

Limaye NEJM 2000:

- D: Kansas, car accident, no history
- 2 kidneys:
  - Montana, Oregon
  - Disseminated histo M8 & M9
- 1 liver : asymptomatic, Ag & Ab neg at 3 yrs
- Pre-grafting serology:
  - 3 Ab negative recipients
  - Donor: 1:16
- Typing (microsatellite polymorphism) : identical genotypes in 2 recipients

Botterel EJCMID 1999

- D: 2 yrs in Guyana
- 1 liver R: ethylic cirrhosis
  - M7: ARDS+ shock: disseminated histoplasmosis
- No infection in other recipients

Evaluation and management of histoplasmosis in living donor after pre-transplant workup

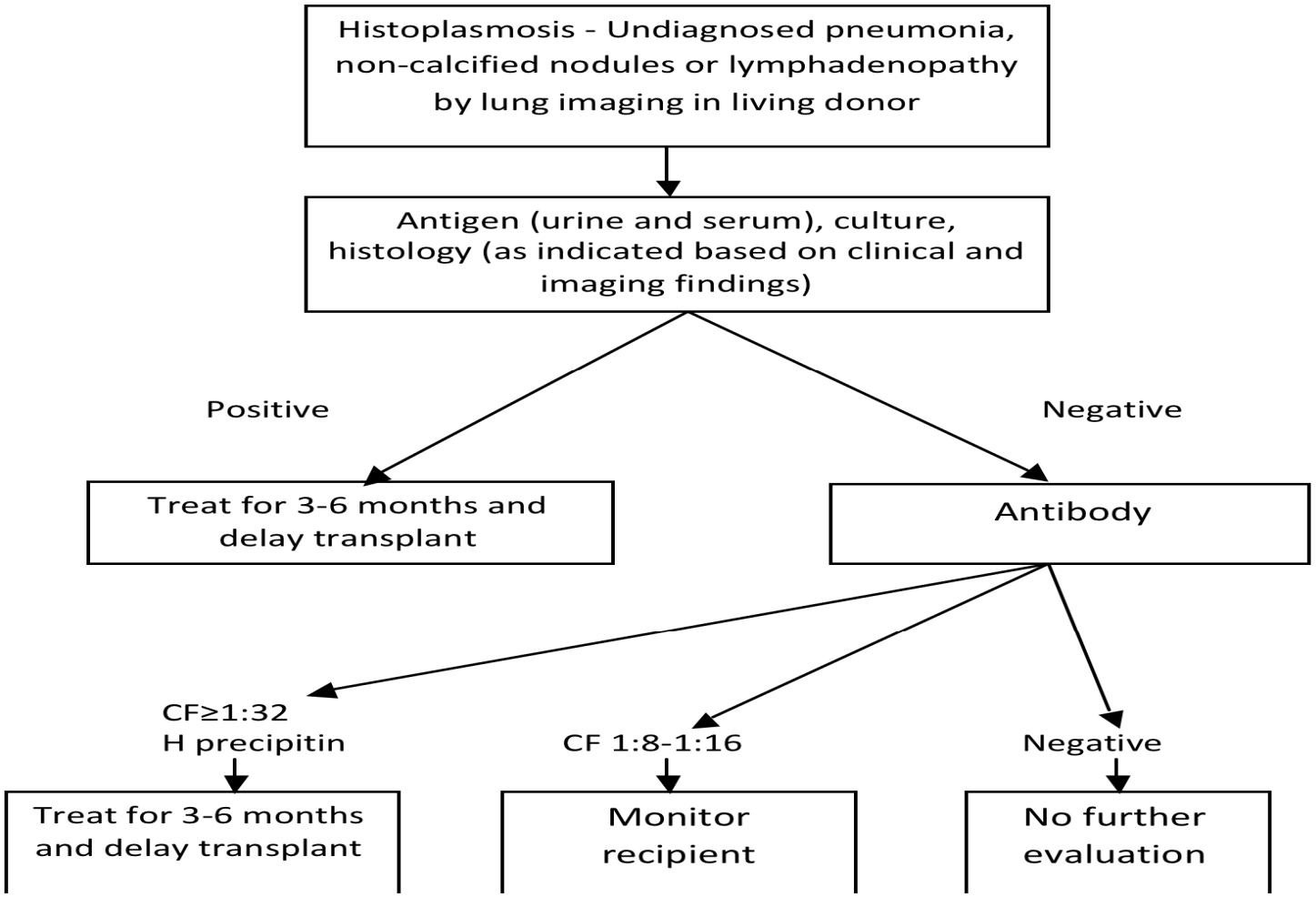

Guidelines of the American Society of Transplantation, Infectious Diseases Community of Practice Singh et al. AJT In press

Coccidioidomycosis & SOT

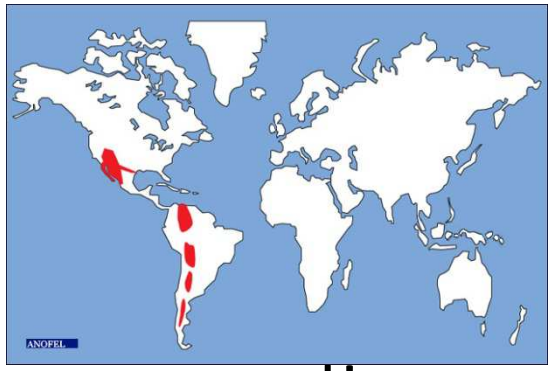

- 150,000 cases per year in USA
- 1.5-8.7% of SOT in endemic areas (1st yr)
- Primary-infection in european SOT recipients = travel!
- Reactivation+++ : > 6 mo PT;

Graft-transmitted coccidioidomycosis… in Paris!

- **50 yrs-old man, underwent a single-LTx for severe idiopathic fibrosis**
- **Acute rejection episodes treated with steroids**
- **Itraconazole administered for > 12 mo for suspected IA**
- **Uneventful until month 35 post-transplant where a graft dysfunction occurred : culture of bronchial aspirate grew : *C. immitis***

- Acquisition of *C. immitis* attributed to a transmission from the donor graft :
  - (1) recipient never traveled outside France/donor traveled to Arizona
  - (2) his anti-*C. immitis* antibodies were positive at the time of death
  - (3) recipient anti-*C. immitis* antibodies negative pre-transplantation
  - (4) X administrations of itraconazole may explain delayed diagnosis

Brugière, Transplantation 2009

Posttransplantation coccidioidomycosis acquired from donor allograft

Type of Tx (ref)	Time of disease Presentation post-Tx	Serologic results	Diagnosis	Involved organs	Antifungal treatment	Outcome, Follow-up
Liver Tx (3)	Day 13	Donor positive (pre-Tx)	BAL and blood cultures Autopsies of recipient and donor	disseminated	FCZ, AmB	Died (day 17)
Kidney Tx (3)*	Day 17	Donor positive (pre-Tx)	BAL and blood cultures Autopsies of recipient and donor	disseminated	FCZ	Died (day 19)
Lung Tx (4)	Day 6	Recipient negative (pre-Tx)	Bronchial washings Autopsy of donor	lung	FCZ	Alive, (12 months) Lifelong FCZ therapy
Lung Tx (5)	Day 21	NA	Autopsy of recipient	disseminated	none	Died (1 month)

Brugière, Transplantation 2009

2nd situation: contamination of preservation fluid

Contamination of preservation fluid

- From a non-infected donor
- Results known 48h after transplantation
- 2 mechanisms:
  - Organ contamination during sampling (digestive leakage, translocation at the time of mesenteric clamping) then contamination of preservation fluid
  - Preservation fluid contaminated first then the organ

Contamination of preservation fluid

- Bacteria
  - ATB in the recipient?
  - Yes if microorganism with vascular tropism (*S. aureus / P. aeruginosa*)
  - For how long?
- Fungi
  - *Aspergillus* *Garrido AJKD 2003*
    - 2 kidneys from the same donor
    - Iliac artery pseudoaneurysm *Aspergillus* sp. isolated in vascular wall
    - 6 mo post transplantation
    - Liver/heart R did not develop aspergillosis.
    - probable preservation fluid contamination
  - *Candida* spp *Albano 2009 Matignon 2008*

Evidence that Graft-Site Candidiasis after Kidney Transplantation Is Acquired during Organ Recovery: A Multicenter Study in France

L. Albano,[1] S. Bretagne,[2,3] M. F. Mamzer-Bruneel,[4] I Kacso,[1] M. Desnos-Ollivier,[3] P. Guerrini,[5] T. Le Luong,[5] E. Cassuto,[1] F. Dromer,[3] and O. Lortholary,[3,6] for the French Mycosis Study Group

Clinical Infectious Diseases Jan 2009

Graft site candidiasis during kidney transplantation in France

- Retrospective national study in France:
  - 9 yrs: 1997-2005
  - All cases of *Candida* spp infected kidney grafts
  - Incidence, origin, characteristics, and outcome of grafts with localized Candida spp. infection occurring post transplantation
  - Centralization of isolates and genotyping when feasible
  - Drain, preservation fluid and renal graft cultures

Albano et al. CID 2009

Graft site candidiasis during kidney transplantation in France

- Incidence:
  - 18 infected recipients from 12 donors / 18617 kidney transpl
  - Incidence ~ 1‰
  - All donors non infected by Candida/digestive leakage in 7/12
- Clinical presentation:
  - 14 arteritis including 13 aneurysms
  - 2 abscesses
  - 1 urinoma
  - 1 infection of surgical site
- First symptoms 25 d (median) after transplantation

Renal arteritis due to *Candida* spp.

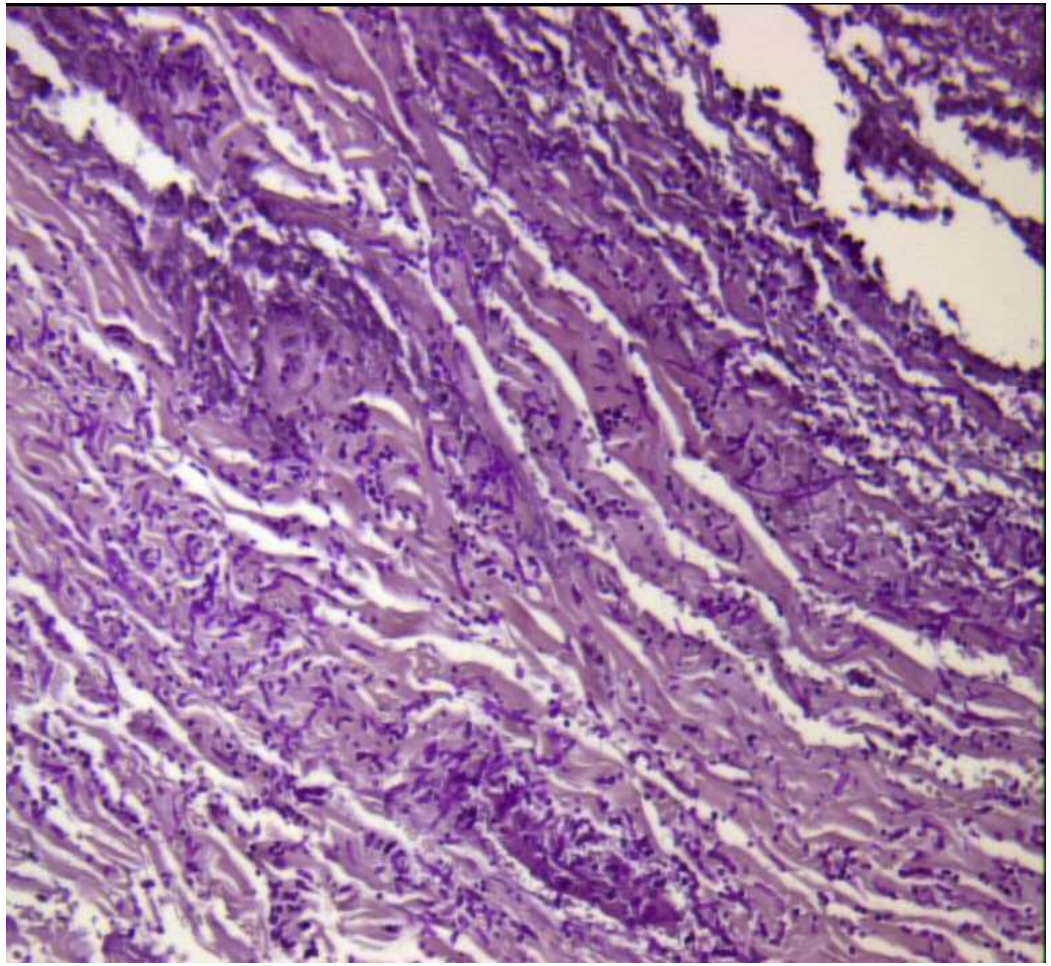

Detailed mycological results

- All but one preservation fluid cultured
  - *Candida* sp (n=8)
  - *Candida* sp + enteropathogens (n=2)
  - Enteropathogens (n=2)
  - Sterile (n=4)
- 2 rare species (*C. dubliniensis* & *C.palmeoliophila*) found in 2 pairs of liver and kidney recipients
- 7 identical *Candida albicans* genotypes found in 5 pairs of kidney recipients and 2 liver and kidney recipients
- For 6 episodes, preservation fluid was contaminated by the same isolate than that found in symptomatic recipients

Albano et al. CID 2009

Arteritis (n=14)

- Antifungal therapy (n=12)
  - 1 prophylactic: fluconazole 3 days
  - 11 curative with fluconazole ± combination
- Surgical therapy (n=11): 9 nephrectomy + 2 functional grafts
  - Nephrectomy + vascular surg (n=5)
  - Nephrectomy then vascular surg (n=2)
  - Nephrectomy (n=2)
  - Conservative surgery + vascular surg (n=2)
- 3 deaths due to intra-abdominal hemorrhage
  - (1 receiving fluconazole since 3d)

Recommandations in France

- Mention digestive leakage from donor to all transplant teams in charge of recipients
- PF, drains should be cultured on adequate media
- If PF culture positive for *Candida* spp.
  - No systematic detransplantation (Matignon 2008)
    - Positive PF culture is not always associated with IFI in the recipient
    - PF+ in 3.6% of 222 recipients: 0 complication when fluconazole administered
  - Inform transplant teams in charge of recipients
  - Treat by fluconazole ≥ 200 mg/d ≥ 1 month
  - Vascular anastomosis should be monitored by doppler
  - When diagnosis of arteritis made: surgical emergency

Corneal graft transmitted fungal infections

- observations of candidiasis (*C.albicans* & *C. glabrata*) [Al-Assiri, Cornea 2006; Sutphin, Am J Ophtalmol 2002]
  - Prophylaxis if culture + in donor

- Two observations of cryptococcosis (*C. albidus*)

  [de Castro, Cornea 2005; Perry Am J Ophtalmol 1990]

Conclusion

- Graft-transmitted IFI should always be suspected in case of early occurrence of IFI during SOT
- Be aware of renal transplant tourism…
- Increased number of donors coming from endemic areas (19% in Spanish cities)
  - Increased risk of graft-transmitted IFI
  - Caution with French living donors who may have traveled in endemic areas
- (Discuss US) systematic preservation fluid fungal culture
- If positive: diagnostic strategy + antifungal therapy and…
- Immediately alert other centers in case of multiple SOT
- National/Guidelines of the AST, Infect Dis Community of Practice